

WHAT IS THE OPTIMAL METHOD TO DIAGNOSE LEVATOR AVULSION ON TOMOGRAPHIC ULTRASOUND IMAGING?

Hypothesis / aims of study

Avulsion of the puborectalis muscle is a common consequence of vaginal childbirth(1) and associated with female pelvic organ prolapse, especially of bladder and uterus (2). Avulsion can be diagnosed by palpation, but the technique requires substantial teaching and seems less repeatable than imaging. The most practical and cost-effective imaging method currently employed to diagnose avulsion is tomographic translabial volume ultrasound(3). It is highly repeatable; however, defects may be detected in multiple planes, raising the issue of how to grade trauma that is not visible in all slices. We undertook a retrospective study in order to define optimal criteria for the diagnosis of avulsion on tomographic pelvic floor ultrasound.

Study design, materials and methods

We retrospectively analysed 764 datasets of women referred to a tertiary urogynecological service for symptoms of prolapse or lower urinary tract dysfunction from May 2005 to November 2008. All had undergone an interview, clinical assessment using the ICS POPQ for prolapse grading and 4D translabial ultrasound, the latter performed supine after bladder emptying on maximum valsalva and on pelvic floor muscle contraction (PFMC). Blinded offline analysis of volume datasets was performed at least 6 months after the original patient contact using 4D View software blinded to all clinical data. Tomographic ultrasound imaging (TUI) performed on volumes obtained on PFMC, at 2.5mm slice intervals, from 5mm below to 12.5mm above the plane of minimal hiatal dimensions was used for assessment for levator avulsion as previously described(3), see Figure 1. The at rest volume was used in patients failing to perform pelvic floor muscle contraction (n=34). The two lowermost TUI slices (ie, those below the plane of minimal dimensions) were excluded from the analysis.

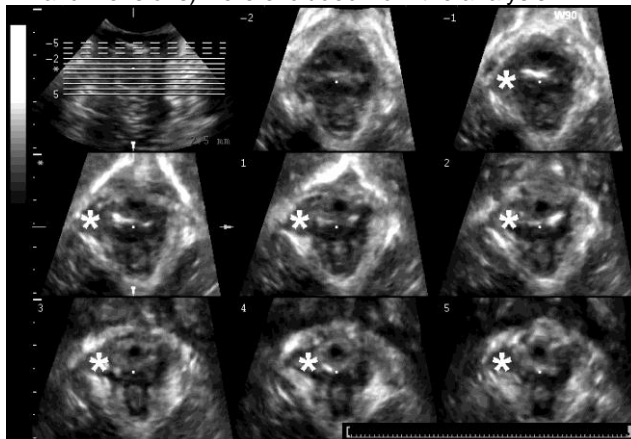


Figure 1: Tomographic ultrasound imaging (TUI) of a levator avulsion (marked by*).

As right- and left- sided defects are not independent of each other, we performed the analysis separately for left and right. We performed logistic regression to determine the relationship between symptoms and signs of prolapse (POP-Q stage 2+) and findings on TUI. As the results on adjacent slices were highly correlated, the information from the slices could not be modelled together. We looked at the relationship between the number of slices with evidence of levator avulsion and symptoms of prolapse. The original model looked at the effect of any 2 slices out of the central 3. Extra slices were added one at a time and the extra information of having an increasing number of slices involved was assessed.

Results

The mean age of 764 patients was 55 (range, 18-89). 89% were vaginally parous (n=682), and the median number of vaginal deliveries was 2 (range, 0-10). 186 (24%) had had a vaginal operative delivery. 33% reported a previous hysterectomy (n=251). They complained of symptoms of stress urinary incontinence (n=541, 71%), urge incontinence (n=524, 69%), frequency (n=399, 52%), nocturia (n=384, 50%) and symptoms of prolapse (n=337, 44%). On examination, 50% (n= 379) were shown to have significant pelvic organ prolapse (ICS POP-Q stage 2 or higher). Of 764 patients, two datasets were not located, and two were impossible to assess, leaving 760 for modelling of the relationship between symptoms of prolapse and defects on TUI. Another 7 patients could not be examined due to vaginal stenosis or refusal, leaving 753 datasets for the analysis of the relationship between significant prolapse and TUI.

In 30% (n=226) we found an avulsion on TUI. It was right- sided in 26% (n= 199), left-sided in 20% (n=146) and bilateral in 16% (n=119). A full avulsion was strongly associated with symptoms of prolapse (38% vs 59%, $P < 0.001$), significant clinical cystocele (74% vs 40%, $P < 0.001$) and cystocele descent on ultrasound ($P < 0.001$). Table 1 shows the effect of all named slices having defects compared to no slices having defects in different models for predicting symptoms of prolapse. In agreement with clinical experience the relationship was not linear. Optimal performance was achieved by a model including all three central slices, i.e., the slice at the plane of minimal dimensions plus the two above. This was true for both the left and the right side. On performing the analysis for objective findings of significant prolapse, this pattern was repeated (see Table 2).

	Left	Right
any 2 of central 3 slices	1.43 (0.62-3.30), P=0.40	0.92 (0.43- 1.99), P= 0.83
all central 3 slices	2.30 (1.64- 3.43), P< 0.001	2.49 (1.71- 3.63), P< 0.001
central 3 plus next above	2.37 (1.67- 3.36), P< 0.001	2.43 (1.66- 3.56), P< 0.001
central 3 plus next 2 above	2.35 (1.65- 3.35), P< 0.001	2.53 (1.72-3.72), P< 0.001
central 3 plus next 3 above	2.35 (1.65- 3.35), P< 0.001	2.52 (1.71- 3.71), P< 0.001

Table 1: Results of logistic regression modelling findings on tomographic ultrasound against symptoms of prolapse (n=760).

Model (n=753)	Odds Ratio (CI) for significant prolapse (Stage 2+)	
	Left	Right
any 2 of central 3 slices	1.99 (0.84- 4.75), P=0.12	1.18 (0.56- 2.49), P= 0.66
all central 3 slices	3.46 (2.41- 4.98), P< 0.001	3.94 (2.60- 5.97), P< 0.001
central 3 plus next above	3.62 (2.49- 5.26), P< 0.001	3.98 (2.60- 6.09), P< 0.001
central 3 plus next 2 above	3.74 (2.55- 5.49), P< 0.001	3.88 (2.53- 5.95), P< 0.001
central 3 plus next 3 above	3.39 (1.05- 10.97), P< 0.001	3.90 (2.54- 5.98), P< 0.001

Table 2: Results of logistic regression modelling findings on tomographic ultrasound against significant objective prolapse (ICS POP-Q stage 2 or higher, n=760).

Interpretation of results

Avulsion of the puborectalis muscle is common and has significant clinical repercussions. A full assessment of patients suffering from female pelvic organ prolapse needs to include evaluation of the levator ani. To date, several different methodologies have been proposed, with multislice or tomographic ultrasound being the most practical and repeatable. This study provides, for the first time, objective data allowing us to optimise diagnostic algorithms. Clinically, it appears that significant trauma is defined by a complete absence of muscle on the inferior pubic ramus which, by definition, would include the entire puborectalis muscle. The imaging equivalent of such palpatory findings seems to be an abnormal muscle insertion in at least three tomographic slices obtained at the level of the plane of minimal dimensions as well as 2.5 and 5 mm above. In the present study we have shown that fewer than 3 abnormal central slices are much less likely to be associated with symptoms and signs of prolapse. Requiring more cranial slices to be positive does not improve model performance.

Concluding message

We propose to diagnose a full puborectalis avulsion on TUI if all three central slices, i.e., the plane of minimal dimensions plus slices 2.5 mm and 5 mm cranial to this plane, show an abnormal insertion of the levator ani on the inferior pubic ramus.

References

1. Obstet Gynecol 2005;106:707-712
2. Br J Obstet Gynaecol 2008;115:979-984
3. Ultrasound Obstet Gynecol 2007;29:329-334

Specify source of funding or grant	Nil
Is this a clinical trial?	No
What were the subjects in the study?	HUMAN
Was this study approved by an ethics committee?	Yes
Specify Name of Ethics Committee	SWAHS HREC
Was the Declaration of Helsinki followed?	Yes
Was informed consent obtained from the patients?	No