

RELAXIN AND GONADAL STEROID RECEPTORS IN UTEROSACRAL LIGAMENTS OF WOMEN WITH AND WITHOUT PELVIC ORGAN PROLAPSE

Hypothesis / aims of study:

Molecular mechanisms leading to pelvic organ prolapse (POP) are poorly understood. Risk factors for the development of pelvic floor weakness include pregnancy and childbirth hinting at a potential role for hormones necessary for human reproduction. Relaxin, a peptide hormone produced in the ovary, the breast and placental tissues has been shown to soften collagenous tissue structures most notably the pubic symphysis to facilitate delivery (1). Similar mechanisms for both disintegration and repair of pelvic floor tissues have been proposed for progesterone and estrogen.

To elucidate possible influences of these hormones, we performed this study assessing the differential expression of estrogen receptor alpha, estrogen receptor beta, progesterone receptor and relaxin receptor mRNA and protein in human uterosacral ligaments obtained during hysterectomy in women with and without POP.

Study design, materials and methods:

Women who were scheduled for hysterectomy because of benign disease were eligible for enrollment after complete urogynecological examination. Specimens of uterosacral ligaments were obtained from 14 women with pelvic organ prolapse stage II and III and 13 women without POP. Both groups did not differ significantly in menopausal status but differed significantly in their parity (2.7 vs 1.0). To assess expression and cellular distribution of receptor proteins, immunohistochemistry was performed with validated antibodies against estrogen receptor alpha (ER alpha), estrogen receptor beta (ER beta), progesterone receptor (PR) and relaxin receptor 1 (LGR-7) proteins. The respective mRNA expression of these receptors as well as of relaxin receptor 2 (LGR-8) was assessed by quantitative real-time polymerase chain reaction (RT-QPCR). A power calculation demonstrated that with a sample size of 12+12 the study has a power of 0.80 to detect a difference of $d=1.2$ in estrogen receptor alpha expression at a significant level of 0.05 based on the results of a published study in vaginal wall tissue (2).

Results:

Strong nuclear staining of ER alpha protein was detected in each specimen in smooth muscle cells of both groups. The fibrous non-muscular connective tissue as well as the endothelium of the ligamental vessels was negative for ER alpha.

Moderate to strong nuclear staining of ER beta protein was detected in nuclei of endothelial cells of ligamental vessels but not in fibrous or muscular tissue independent of POP.

Staining of PR protein was similar to that of ER alpha, with consistent strong nuclear staining of smooth muscle cells but negative staining of connective tissue and vessels.

Low to moderate staining of LGR-7 could be detected in 50-60% of smooth muscle cell nuclei with minimal staining of the cytoplasm. The nuclei and cytoplasm of fibrous connective tissue stained consistently negative. The endothelium of ligamental vessels showed consistent moderate staining of the nucleus and to a lesser extent of the cytoplasm.

Table 1: Cellular localization of proteins in immunohistochemistry: nuclear staining (- negative, + minimal, ++ moderate, +++ strong staining)

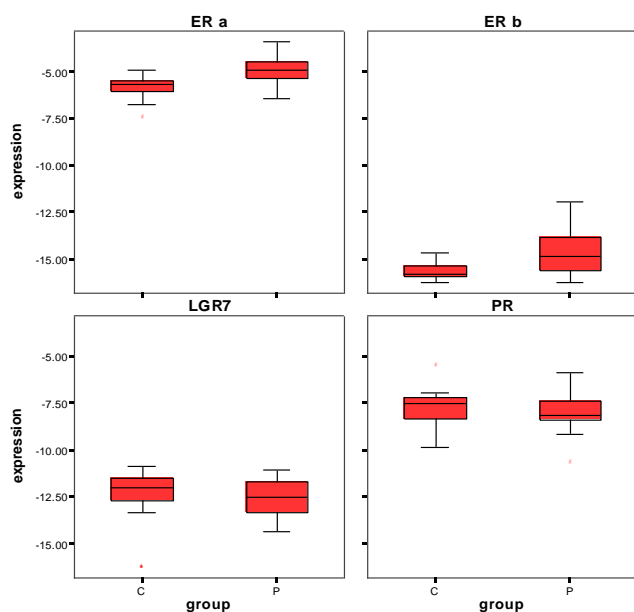
antibody	smooth muscle cells	fibrous connective tissue	ligamental vessel endothelium
ER alpha	+++	-	-
ER beta	-	-	+ / ++
PR	+++	-	-
LGR-7	+ / ++	-	++

Messenger RNA transcripts for ER alpha, ER beta, PR and LGR-7 could be detected in all patients of both groups, LGR-8 could only be detected in 1 patient of the control group in very low amount.

ER alpha and ER beta mRNA expression was significantly higher in the uterosacral ligaments in women with POP: ER alpha: $p=0.004$, ER beta $p=0.008$ (T-test).

PR and LGR-7 mRNA expression did not differ significantly between women with and without POP: PR: $p=0.65$, LGR-7: $p=0.85$.

Figure 1: Box plots of RT-QPCR (P = pelvic organ prolapse, C = controls)



Interpretation of results:

Both, estrogen and progesterone receptors are regularly expressed in uterosacral ligaments of pre- and postmenopausal women. Existence of POP is associated with higher ligamental expression of ER alpha and ER beta, possibly to mediate repair mechanisms due to stretch injury as has already been described in blood vessels (3).

This first examination of ligamental relaxin receptors revealed regular expression of LGR-7 but absence of LGR-8, independent of POP. Women in the POP-group may have had a higher total lifetime relaxin exposure because of their higher parity that might have contributed to development of POP via regularly expressed ligamental LGR-7.

Concluding message:

Involvement of altered estrogen signalling via ER alpha and ER beta - but not that of progesterone - is likely in uterosacral ligaments affected by POP.

A local effect of relaxin on uterosacral ligaments needs to be further clarified because of the constitutive ligamental expression of LGR-7.

References

1. Wilkinson TN, Speed TP, Tregear GW, Bathgate RA. Evolution of the relaxin-like peptide family. BMC Evol Biol 2005;5:14.
2. Xie Z, Shi H, Zhou C, Dong M, Hong L, Jin H. Alterations of estrogen receptor-alpha and -beta in the anterior vaginal wall of women with urinary incontinence. Eur J Obstet Gynecol Reprod Biol 2007;134:254-8.
3. Li HJ, Haque Z, Lu Q, Li L, Karas R, Mendelsohn M. Steroid receptor coactivator 3 is a coactivator for myocardin, the regulator of smooth muscle transcription and differentiation. Proc Natl Acad Sci U S A 2007;104:4065-70.

Specify source of funding or grant	NONE
Is this a clinical trial?	No
What were the subjects in the study?	HUMAN
Was this study approved by an ethics committee?	Yes
Specify Name of Ethics Committee	Ethics-Committee of the Medical University of Vienna and the Vienna General Hospital - AKH
Was the Declaration of Helsinki followed?	Yes
Was informed consent obtained from the patients?	Yes