

ULTRASONOGRAPHIC SCAN TIMING IN THE EVALUATION OF SYNTHETIC MESH IN VAGINAL CYSTOCELE REPAIR.

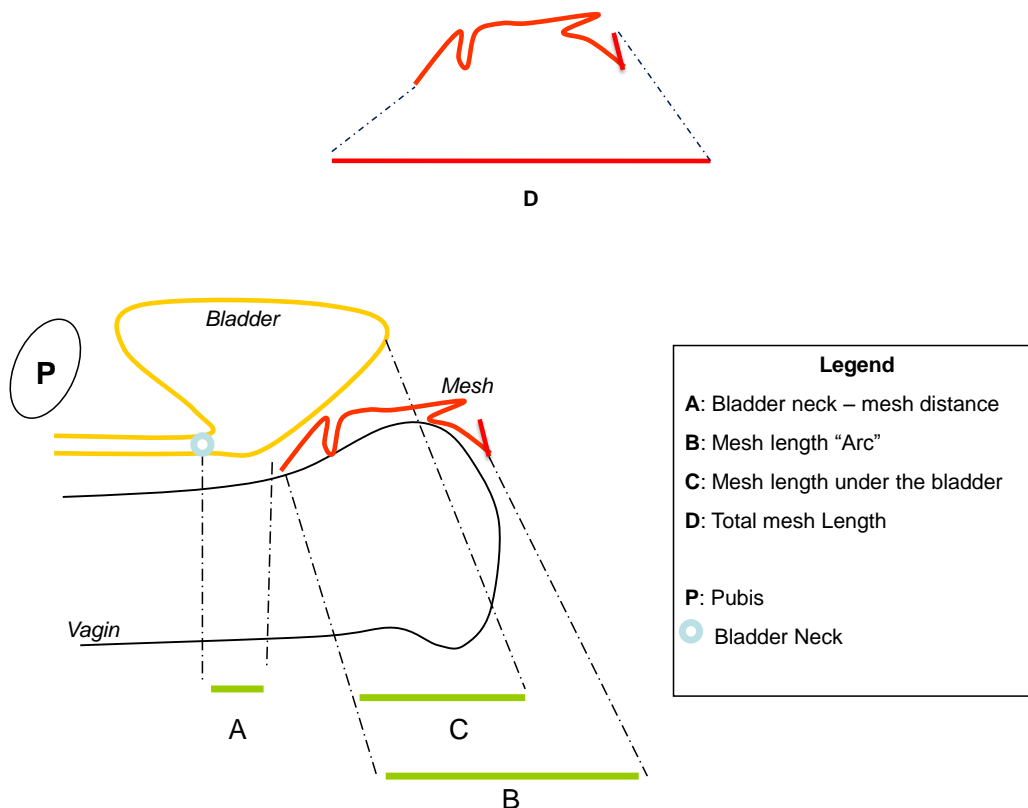
Hypothesis / aims of study

Ultrasonographic scan shows synthetic mesh used in vaginal cystocele repair. Pelvic position and contraction of the mesh can be followed up after surgery^{1,2}. Dislodgement and contraction are pointed to be a part of mesh complication repair, for prolapse recurrence. However, timing for ultrasonographic scans must be standardized. Surgical procedure influences multi parameters to localize the mesh.

The main objective was the evaluation of the mesh contraction after surgery by defining with measurement and which period can notice information.

Study design, materials and methods

Thirty patients with a cystocele repair had the same procedure with polypropylene mesh, four arms trans obturator, Ugtex™ (Sofradim, Covidien™). Patients had systematically bladder derivation for 2 days and intra-vaginal pack during one night. The mesh was measured pre operatively (PO). Ultrasonographic scan was performed 2D/3D; intra vaginal and trans perineal, at the end of the procedure (D0), at 3 day (D3) and 6 week (W6) follow up. 3D mesh reconstruction and intra vaginal scan permit a double checking of measurements. We evaluated mid-sagittal length of the mesh, anatomic place, distance to bladder neck and mesh area. We defined the "arc" of the mesh, distance between the two most opposite points of the mesh under vagina.



Results

Total mesh length in mid-sagittal plan is equal at D0 and D3 compare to pre operative clinical examination. Mesh contraction between W6 and PO was estimated to 30% (+/-8).

Mesh size decreased to 45% (+/-5) between PO and D0. Mesh increased to 12% (+/-2) between D0 and D3. From D3 to W6, mesh arc and total mid sagittal mesh length retracted to 13% (+/-2).

Interpretation of results

