

RECTAL INTUSSUSCEPTION IS ASSOCIATED WITH ABNORMAL LEVATOR STRUCTURE AND MORPHOMETRY

Hypothesis / aims of study

Anorectal symptoms are common in urogynecological patients, and so are anatomical abnormalities of the anorectum associated with such symptoms. This study investigates rectal intussusception (RI). RI is defined as an infolding of the full thickness of the rectal wall, without protrusion from the anus. It is distinct from rectal prolapse, in which there is protrusion through the anus. While rectal prolapse is associated with major symptoms, intussusception may be asymptomatic(1). We aimed to define the prevalence of rectal intussusception in a urogynaecological population and to describe associated symptoms, signs and ultrasonic findings, in particular those relating to pelvic floor function and anatomy. It was hypothesized that rectal intussusception is associated with abnormal levator anatomy and function.

Study design, materials and methods

This retrospective study was undertaken by reviewing the electronic records and volume imaging datasets of 967 women seen in a tertiary urogynaecological clinic between May 2005 and March 2009. All had undergone an interview, a vaginal examination and translabial ultrasound (Voluson 730 expert system, GE Kretz Ultrasound, Zipf, Austria) to determine pelvic organ descent as well as structure and function of the levator ani muscle. During vaginal examination, prolapse was graded using the ICS POP-Q grading, and levator strength and integrity were also assessed by palpation at the time of the original examination. Ultrasound imaging analysis was performed offline in November/ December 2009 by the first author, using proprietary software (Kretz 4D View V 5.0) on a PC, with the operator blinded against all clinical data.

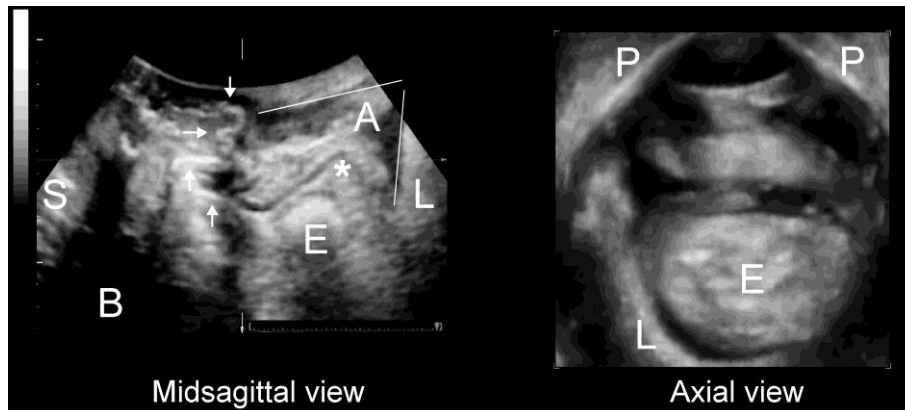


Figure: Rectal intussusception after clinically successful Apogee mesh (arrows). There is splaying of the anal canal (see lines). The apex of the intussuscepti is identified by *. The axial view shows severe ballooning of the hiatus. S= symphysis pubis, B= bladder, E= enterocele, A= anal canal, L= levator ani, P= inferior pubic ramus.

Hiatal area at maximum Valsalva was measured at the plane of minimal hiatal dimension using a technique published previously(2). This plane is identified in the mid-sagittal plane as the minimal distance between the symphysis pubis and the anterior margin of the central aspect of the puborectalis muscle. This parameter was normally distributed. Levator avulsion was diagnosed on tomographic imaging (TUI) as described previously (3), if slices obtained at the plane of minimal dimensions as well as 2.5 and 5 mm cranially showed an abnormal muscle insertion, and if palpation confirmed complete avulsion of the muscle.

Results

The mean age was 55.1 (range, 17- 90). 90% were vaginally parous, 25% (240/962) had had a vaginal operative delivery. 34% reported a previous hysterectomy (326/965). Patients complained of symptoms of stress urinary incontinence (n=675, 70%), urge incontinence (n=654, 68%), frequency (n=489, 51%), nocturia (n=479, 50%) and symptoms of prolapse (n=421, 44%). As regards symptoms of bowel dysfunction, patients complained of straining at stool (n=320, 33%), incomplete bowel emptying (n=322, 33%), vaginal digitation (n=108, 11%), pain on defecation (n= 102, 11%) and fecal incontinence (n=115, 12%). Eight patients had not been examined clinically, leaving 959. On examination, 51% (n= 487) were shown to have significant pelvic organ prolapse (ICS POP-Q stage 2 or higher). This was a cystocele in 38% (n=364), uterine prolapse in 7% (n=66) and a rectocele in 28% (n=272).

In 22% of all patients (n=209) we found an avulsion of the puborectalis muscle on digital clinical examination and TUI. It was right- sided in 19% (n= 187), left-sided in 12% (n=114) and bilateral in 10% (n=91). The area on maximal Valsalva was available in 953 women (14 could not be retrieved due to data corruption or clerical error) and measured 27.7 cm² (range, 6.12- 67.5). Of 967 women, 3.9% (n= 38) were diagnosed with a rectal intussusception. Intussusception was associated with age (60.1 [SD 12.2] vs 54.9 [SD 14.3], P= 0.014), vaginal childbirth (P= 0.037 on X2) and previous hysterectomy (305/927 vs 21/38, P= 0.004) as well as previous anti- incontinence or prolapse procedure (193/929 vs. 20/38, P<0.001) but not with vaginal operative delivery (P= 0.85).

Intussusception was not associated with straining at stool (X2, P=0.62) or pain on defecation (P= 0.28), but with incomplete emptying (298/928 vs. 24/38, P< 0.001), digitation (95/928 vs 13/38, P<0.001) and weakly with fecal incontinence 106/928 vs. 9/38, P= 0.022). It was also associated with symptoms of prolapse (P= 0.005), but only weakly with objective signs of significant prolapse (stage 2+) on clinical examination (26/37 vs 461/919 , P= 0.016), and this was mainly due to enterocele (4/37 vs 34/918, P= 0.03) and significant rectocele (19/37 vs 253/ 922, P= 0.002). On multivariate regression we tested for a confounding effect of clinical rectocele on the relationship between symptoms and intussusception. Such a confounding effect was demonstrated for incomplete emptying (OR 3.62 (CI 1.85-7.11) before adjusting, and OR 3.17 (CI 1.60- 6.29) after adjustment, for vaginal digitation (OR 4.56 (CI 2.26-9.21) before and OR 3.53, CI 1.69-7.39 after adjustment. A true rectocele as observed on imaging influenced the relationship (OR 5.34, CI 2.60- 11.0) between intussusception and vaginal digitation but had no effect on other symptoms.

Hiatal area on Valsalva	Odds Ratio	Confidence Intervals	P
<25 cm ²	1		
25-<30	3.62	0.86- 15.3	0.081
30-<35	6.7	1.79- 25.0	0.005
35+ cm ²	17.2	5.04-58.75	<0.001

Table 1: Odds ratios for the diagnosis of intussusception relative to hiatal area on Valsalva (n=953)

The area on Valsalva was much higher in women with intussusception (36.9 [SD9.0] vs 27.4 [SD 8.7] P< 0.001 on t-test, and this relationship was nonlinear, see Table 1. Levator avulsion was more common (15/37 vs. 175/ 869 , P= 0.003). However, on multivariate regression the effect of avulsion was fully accounted for by hiatal area on Valsalva. There was no independent effect of avulsion.

Interpretation of results

Rectal intussusception is not uncommon in urogynaecological patients, with a prevalence of 3.9% in this series of 967 women. It is often asymptomatic and associated with symptoms of incomplete bowel emptying, vaginal digitation, fecal incontinence and symptoms of vaginal prolapse. Patients with rectal intussusception are older, more likely to be clinically diagnosed with rectocele and vaginal enterocele, and they are more likely to be vaginally parous and to have had a hysterectomy. Most interestingly, rectal intussusception is associated with avulsion of the levator and with hiatal ballooning, indicating that structural and/or functional impairment of the levator ani may play a role in the pathogenesis of this condition.

Concluding message

Rectal intussusception is associated with abnormal levator structure and morphometry.

References

1. Gut. 1989; 30: 1737-1749
2. Ultrasound Obstet Gynecol 2005; 25: 580-585
3. Ultrasound Obstet Gynecol 2007; 29: 329-334

Specify source of funding or grant	Nil
Is this a clinical trial?	No
What were the subjects in the study?	HUMAN
Was this study approved by an ethics committee?	Yes
Specify Name of Ethics Committee	SWAHS
Was the Declaration of Helsinki followed?	Yes
Was informed consent obtained from the patients?	No