

THE USE OF 4-DIMENSIONAL ULTRASOUND AND TOMOGRAPHIC ULTRASOUND IMAGING (TUI) FOR THE DIAGNOSIS OF PARAURETHRAL MASSES IN WOMEN

Hypothesis / aims of study

A variety of imaging studies are used for the diagnosis of paraurethral masses and suspected urethral diverticulum including voiding cystourethrography, pelvic CT scan and pelvic MRI. 2D ultrasound had been used in the past however, the real-time images are not readily available to the surgeon and the hard images do not give a clear guide for surgical planning. With 4D ultrasound, it is possible to process images into slices similar to that used by computed tomography or nuclear magnetic resonance imaging. The objective of this study is to assess the use of 4-dimensional pelvic floor ultrasound and multislice imaging in the evaluation of paraurethral masses in women.

Study design, materials and methods

Patient demographics, preoperative evaluation data, and surgical outcomes were collected.

Six women who presented in clinic with paraurethral masses from April 2009 to Feb 2010 were included. All underwent basic pre-operative assessment including urodynamics, ie uroflowmetry, measurement of post-void residual and cystometrogram or videocystourethrogram, and pelvic floor ultrasound.

Patients were asked to void immediately prior to ultrasound examination. 2D translabial and 4D pelvic floor ultrasound were then performed using a GE Kretz Voluson 760 Expert System. Images and volumes were acquired both at rest and at valsalva. On 2D translabial ultrasound, the midsagittal plane was used to identify the urethral mass and the neck of a suspected diverticulum if present.

With 4D ultrasound, acquisition of images was performed with the main axis of the transducer in the mid-sagittal plane with the urethra and bladder neck providing points of reference. Acquired volumes were then analyzed with multislice imaging or tomographic ultrasound imaging (TUI) using the GE Kretz 4D View (Kretztechnik GmbH, Zipf, Austria) v7.0 software. The plane of minimal dimensions (as described by Dietz) was the plane of reference with 2.0-mm steps recorded below and above this plane to encompass the whole length of the urethra.

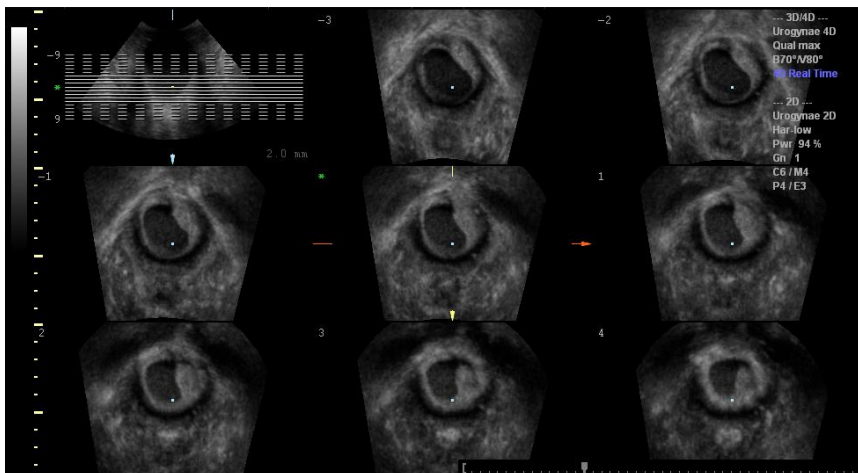


Figure 1: Tomographic ultrasound imaging of a urethral diverticulum.

Intra-operatively, a cystoscopy was performed at the start of each procedure. A diverticulum was identified in 4 cases. These patients underwent diverticulectomy. One patient underwent excision of vaginal cyst and one had an anterior colporrhaphy. Where applicable, specimens were sent for histopathology.

Results

The median age is 41(R30-64)years and the median parity is 2(R0-4). None of the patients had prior urethral surgery or previous pelvic floor surgery. The cohort had a variety of symptoms with the most common being 'lump in the vagina', incontinence, and discharge.

Ultrasound was able to identify 4 cases of urethral diverticulum, 1 case of vaginal cyst, and 1 normal urethra. The neck of the diverticulum was identified in all 4 cases on 2D scan and TUI.

Five of the six women have undergone operations. One is still awaiting surgery as she is currently 37 weeks pregnant. Intra-operative findings confirmed the ultrasound findings. Specimens sent for histopathology were also consistent with a diverticulum in the 4 identified cases and with Gartner's duct cyst in the case suspected as a vaginal cyst.

Interpretation of results

In this small series, 4D ultrasound and TUI had accurately identified the paraurethral pathology in every case. It was able to identify the neck of the diverticulum and its relation to the bladder neck which helps in surgical planning.

Concluding message

Our experience has shown that 4D ultrasound and tomographic ultrasound imaging provides valuable information and may be used as a first-line test for the evaluation of paraurethral masses.

<i>Specify source of funding or grant</i>	None
<i>Is this a clinical trial?</i>	No
<i>What were the subjects in the study?</i>	HUMAN
<i>Was this study approved by an ethics committee?</i>	No
<i>This study did not require ethics committee approval because</i>	it is an audit.
<i>Was the Declaration of Helsinki followed?</i>	Yes
<i>Was informed consent obtained from the patients?</i>	Yes