

1105

Condrea A¹, Ginath S¹, Golan A¹

1. Wolfson Medical Center, Holon and Sackler Faculty of Medicine, Tel-Aviv, Israel

TRANS-VAGINAL COLPOSACROPEXY: DESCRIPTION OF A NOVEL METHOD AND PRELIMINARY RESULTS.

Hypothesis / aims of study

Colposacropexy is re-emerging as the operation of choice for apical vault prolapse (1). Initially described as a trans abdominal procedure (2), followed by later developments utilizing the laparoscopic approach and recently a combined approach has been described in which the mesh is fixed to the apex of the vagina and posterior wall trans vaginally, and then after closure of the vault, the sacral end of the mesh is attached by laparoscopy (3). It seemed only natural to further advance and explore the possibility of performing colposacropexy exclusively trans-vaginally. The objective of the study is to present the technique of this new operation and report our preliminary results.

Study design, materials and methods

Technique description: After performing vaginal hysterectomy (or opening the apex of the vault in cases of apical vault prolapse post hysterectomy) we sharply dissect the posterior peritoneum off the vaginal mucosa, after identifying the correct plane we continue with digital dissection of the peritoneum up to the sacrum. A Navartil retractor can be inserted into the dissected area for visualization of the presacral area. We then suture a polypropylene tape of 3X15 cm to the vaginal mucosa and down along the rectocele if necessary. The rectum is displaced to the left by a swab on a swab-holder inserted thru the anus. We then invert the tape into the dissected space, feel the bone at the level of S3-5, and under digital control we attach the tape with 2-3 endoscopic tackers (ProTack™ 5mm Fixation Device) (Figure 1). We then close the vaginal cuff. The tension is gauged by leaving a 1st degree apical prolapse to allow for when upright to flatten the tape on the pelvic floor and avoid excess tension and back pain. Additional correction of anterior wall or TOT is made as indicated. Five patients consented and underwent the procedure.

Results

The age of the women ranged 51 to 62. Three women underwent this operation at vaginal hysterectomy, and 2 for post hysterectomy apical prolapse. All the patients underwent the surgery because of symptomatic prolapse (POPq point C +2 and above). No immediate or late complications were recorded the success was complete, with no recurrence of apical prolapse during follow up period of up to one year.

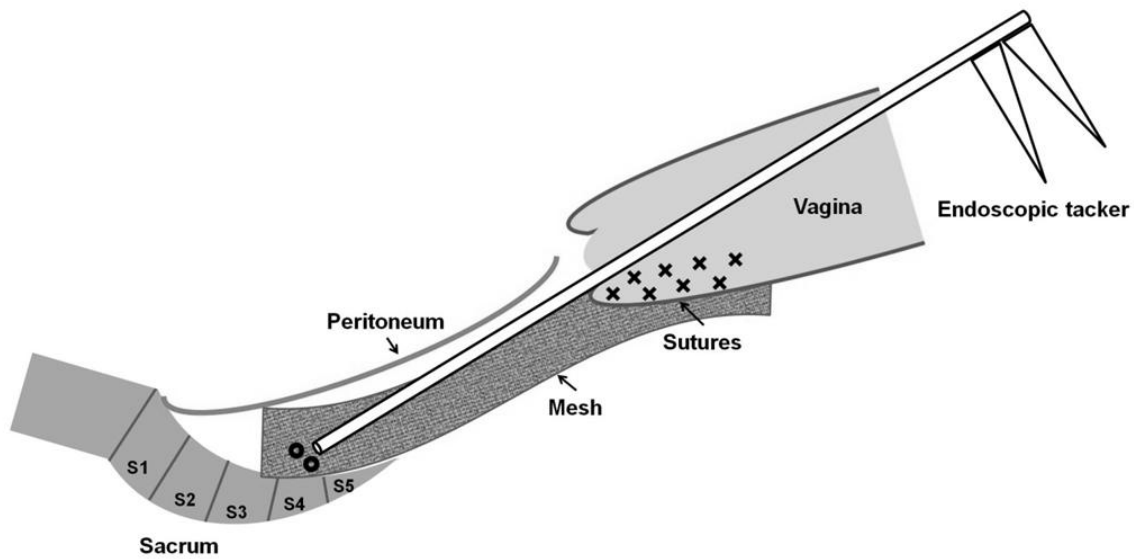
Interpretation of results

Colposacropexy has proved to be the best surgical offer for apical vault prolapse. Yet, the need for laparotomy or laparoscopy makes it unfeasible from many surgeons. Introducing this new technique vaginal technique will offer another alternative, safe and effective which allows for the completion of pelvic floor reconstruction without the need of abdominal or combined abdominal-vaginal procedures.

Concluding message

Trans-vaginal colposacropexy is plausible, safe, effective, and allows the completion of pelvic floor reconstruction without the need of combined abdominal-vaginal procedures.

Figure 1



References

1. Maher C, Baessler K, Glazener CM, Adams EJ, Hagen S. Surgical management of pelvic organ prolapse in women. Cochrane Database Syst Rev. 2007 Jul 18;(3):CD004014.
2. Nygaard IE, McCreery R, Brubaker L, Connolly A, Cundiff G, Weber AM, Zyczynski H; Pelvic Floor Disorders Network. Abdominal sacrocolpopexy: a comprehensive review. Obstet Gynecol. 2004 Oct;104(4):805-23.
3. Montironi PL, Petruzzelli P, Di Noto C, Gibbone C, De Sanctis C, Fedele M. Combined vaginal and laparoscopic surgical treatment of genito-urinary prolapse. Minerva Ginecol. 2000 Jul-Aug;52(7-8):283-8.

Specify source of funding or grant	No.
Is this a clinical trial?	No
What were the subjects in the study?	HUMAN
Was this study approved by an ethics committee?	Yes
Specify Name of Ethics Committee	Helsinki
Was the Declaration of Helsinki followed?	Yes
Was informed consent obtained from the patients?	Yes