

Neurogenic bladder associated with Xeroderma Pigmentosum A in Japan



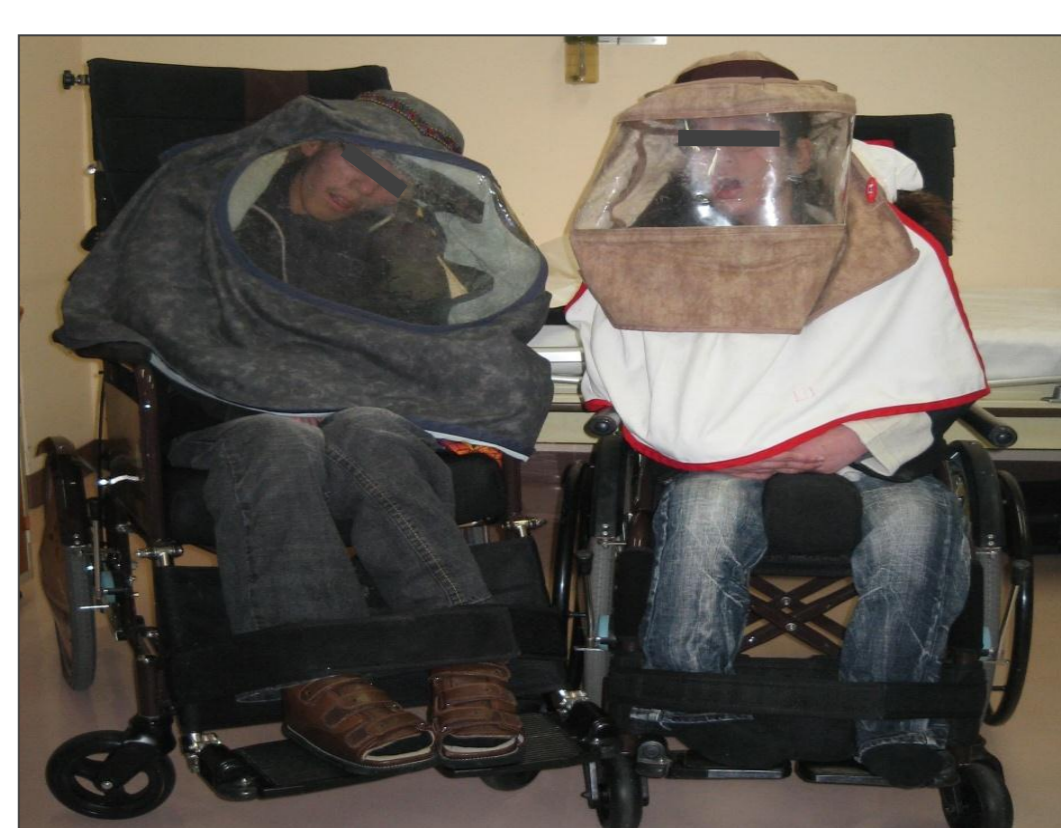Ken-ichi MORI, Yasuhiro SUMINO, Yasuyuki AKITA
Fuminori SATO, Hiromitsu MIMATA

Department of Urology, Oita University Faculty of Medicine, Oita, Japan

Background

Xeroderma pigmentosum (XP) is an autosomal recessive disease characterized by abnormal sensitivity to sunlight which results in pigmentary changes, and eventually carcinoma. XP is classified into nucleotide excision repair deficient types, A through G, as well as a variant type (XP-V). XP occurs at higher frequency in Japan (1:22000) than in the United States (1:250000). Approximately 50% of all Japanese patients with XP are assigned to XP-A and 25% to XP-V. XP-A patients developed neurological dysfunction in childhood. The neurological disease advances in an orderly fashion through its successive stages, finally affecting the whole nervous system. There are few reports about neurogenic bladder of patients with XP.

XP-A patients



Protection against UV lights is always needed

Purpose

To report four cases of neurogenic bladder with XP-A.

Clinical course : XP-A

Childhood: Deafness, Decreased deep tendon reflex
Schoolage:

early stage: Brain atrophy, Equinus foot
late stage: Mental deterioration

Decrease of brain wave activity

Puberty: Gait disturbance (→Wheelchair)
Vocal cord paralysis (→Tracheotomy)
Deglutition disorder (→Gastrostomy)

Adult age : Aspiration pneumonia
Sudden death

Case 1

Case: Male aged 18 years.

Chief complaint: Febrile UTI.

Present illness:

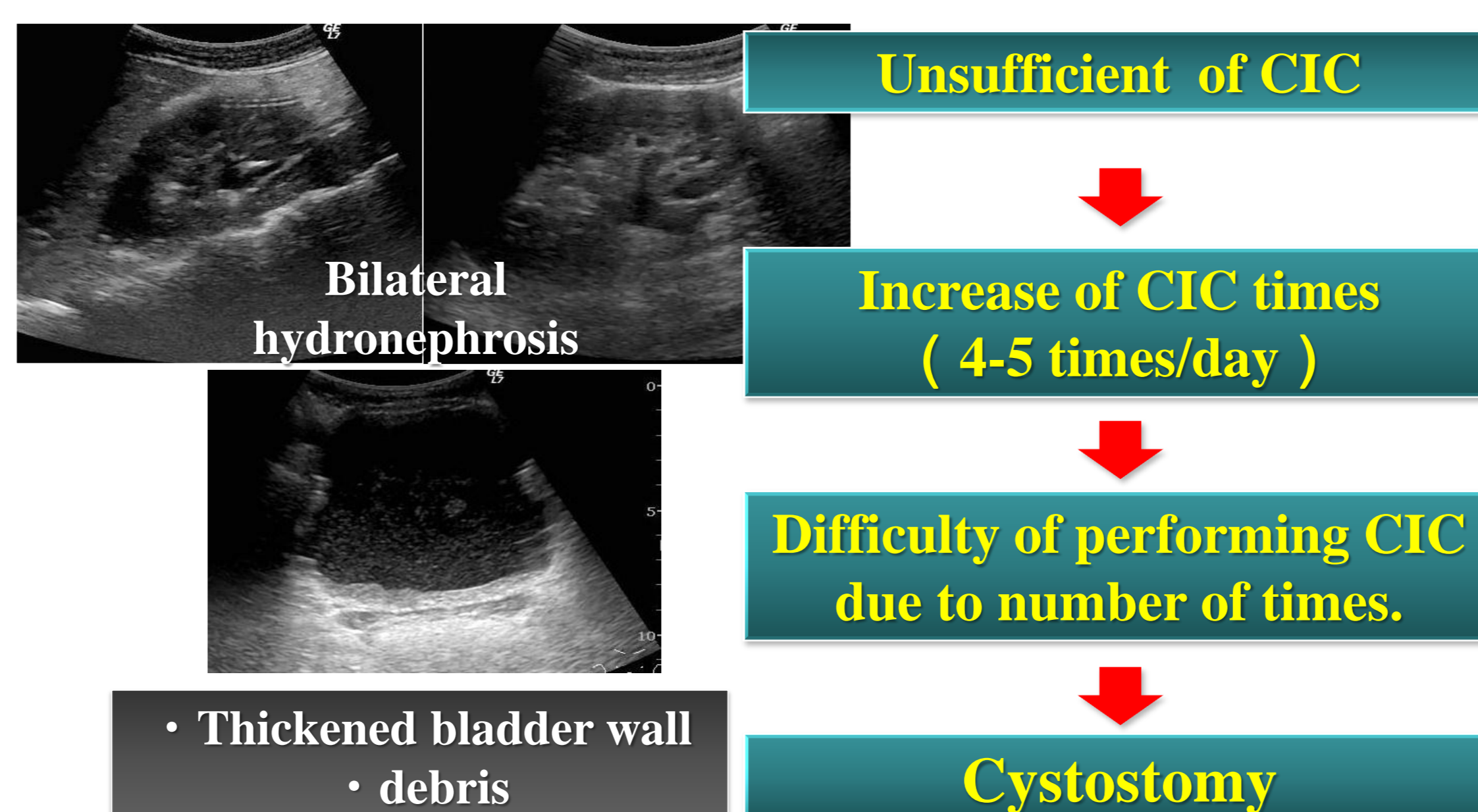
- Natural birth (born at 39 weeks, 3732g).
- At age of 8 months: Hypersensitivity to sunlight with high fever.
- At age of 15 months: Diagnosis of XP-A by genetic testing.
- At age of 12: Pollakisuria.
- At age of 18: Febrile UTI.

Mother performed CIC (3 times/day) for the child around one year due to voiding dysfunction.

Improvement of febrile UTI

Reccurrence of febrile UTI

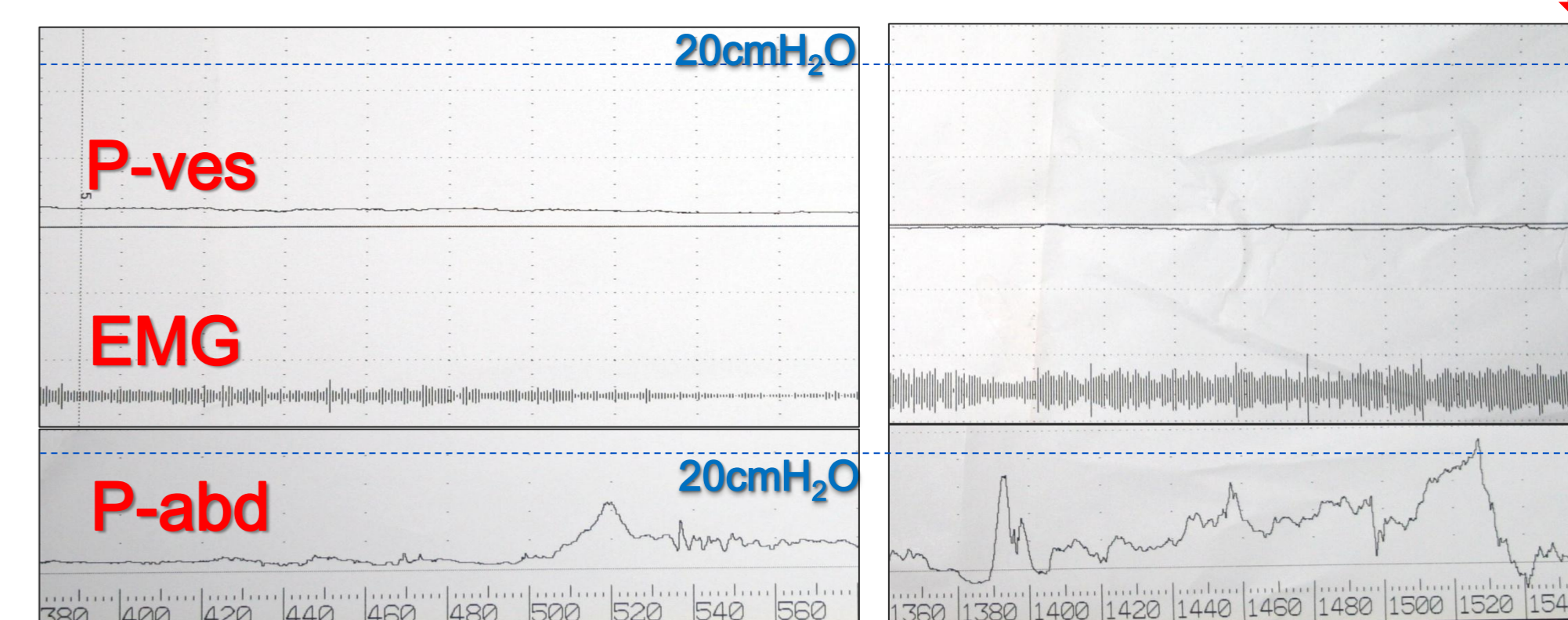
Case 1: cause of recurrent UTI



Case3: Cystometry

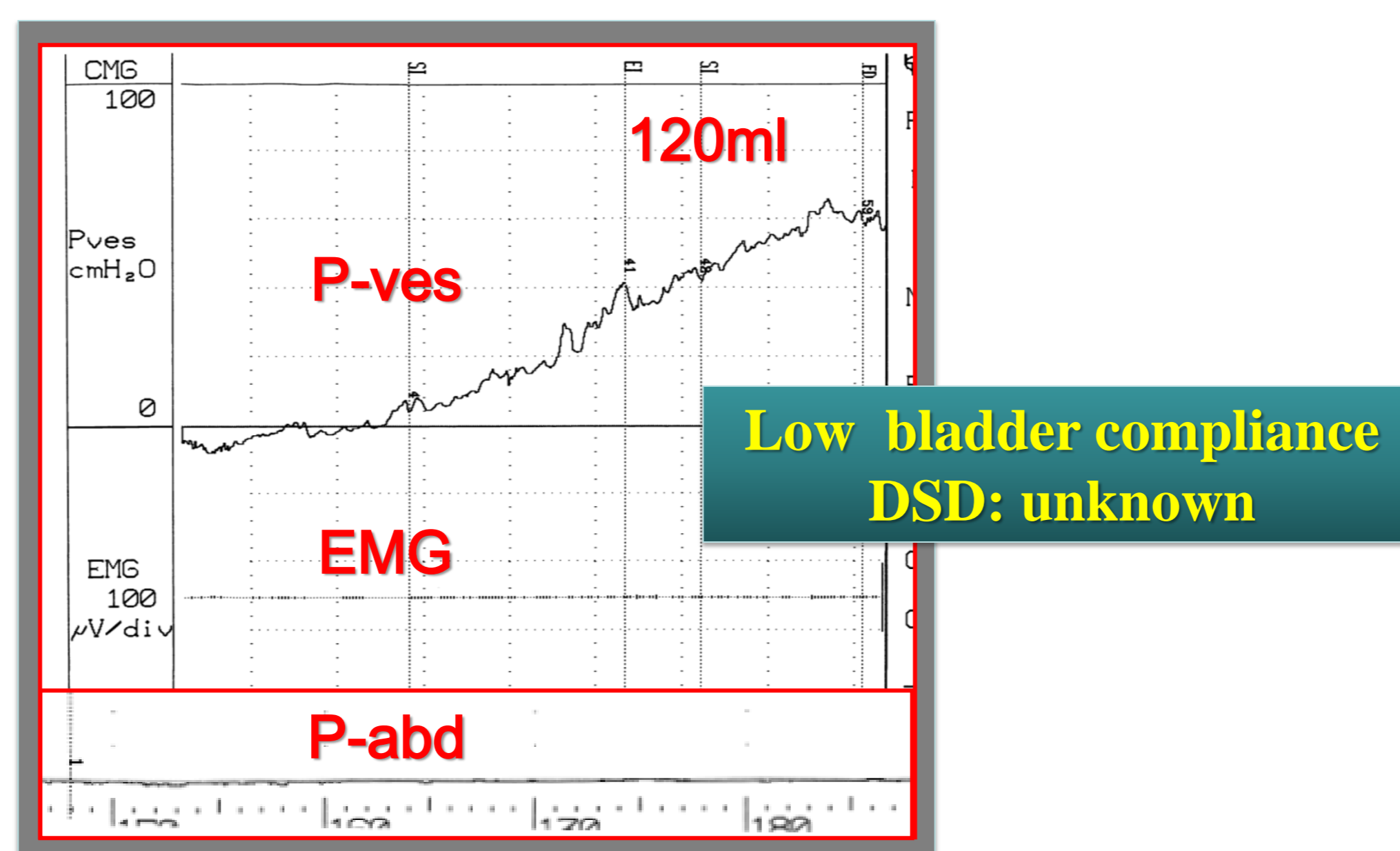
- First desire to void : 250ml
- Strong desire to void: unknown

Bladder filling 400ml



Reduced bladder sensation
DSD: unknown

Case 1: Cystometry



Case4#1

Case: Male aged 18 years

Chief complaint: Febrile UTI

Present illness:

- At age of 10: Gait disturbance.
- At age of 14: Dyspnea, Deglutition disorder.
- At age of 15: Dysuria, Obstipation.
- At age of 18: Febrile UTI

with bilateral hydoronephrosis.

Voiding cystourethrography: VUR(+)

Cystometry: Low bladder compliance, DSD(+)

Case 2

Case: Female aged 13 years

Chief complaint: pollakisuria, dysuria

Present illness:

- Natural birth (born at 33weeks, 2144g).
- Cerebral palsy.
- At age of 4 months: Diagnosis of XP-A.
- At age of 7: Pollakisuria, Dysuria.
- At age of 13: visit us.

Residual urine: 30ml

Follow-up

Case 3

Case: Male aged 16 years

Chief complaint: Asymptomatic pyuria at sometimes

Present illness:

- Natural birth (born at 41weeks, 2964g).
 - At age of 9 months: Diagnosis of XP-A by genetic testing.
 - At age of 16: Urinary retention.
- Medication was started.
(distigmine bromide, prazosin hydrochloride).

Visit us due to asymptomatic pyuria for sometimes

Residual urine: 0ml, Reduced bladder sensation

Voiding regularly with medication (mentioned above)

XP in Japan

- Frequency: 1/22,000 (no gender distinction difference) #2.
 - About 500 XP patients in Japan.
 - There is no correlation between neurogenic disorder and UV irradiation level.
 - Decrease of acetylcholin in central nerve system.
- The efficacy of donepezil hydrochloride is probably possible.**

Discussion

Even nowadays, it has not been known that the XP-A patients become a neurogenic bladder because the number of XP-A patients is very low. The onset of neurological symptoms such as cognitive dysfunction in patients with XP-A is generally observed in early childhood. Furthermore, almost all of the syptoms such as voiding dysfunction could be recognized in schoolage. Therefore, periodic evaluation of voiding function in patients with XP-A should be initiated in their early schoolage.

(References)

- #1. Acta urologica japonica 2009; 55: 461-2.
- #2. Brain 2008; 131: 1979-89.: