

## EFFICACY OF A NARROW-BAND IMAGING CYSTOSCOPY FOR THE DETECTION AND TREATMENT OF HUNNER'S LESIONS IN PATIENTS WITH PAINFUL BLADDER SYNDROME/ INTERSTITIAL CYSTITIS

### Aims of study

The current diagnostic and therapeutic standard for painful bladder syndrome/ interstitial cystitis (PBS/IC) is cystoscopic examination with hydrodistension, usually with white-light imaging cystoscopy (WLI). It is often not easy to diagnose as having PBS/IC by conventional WLI even if clear ulcerative formations such as Hunner's lesions/ulcers are present. Narrow band imaging cystoscopy (NBI) is a novel method, which might improve the detection rate of Hunner's lesions. We aimed to determine prospectively whether NBI improves the detection rate and the number of Hunner's lesions of PBS/IC over WLI in cases suspected of having PBS/IC, and whether NBI-assisted transurethral fulguration (TUF) of Hunner's lesions have a treatment efficacy and reduce PBS/IC recurrence rate.

### Materials and methods

During the period of December 2009 through September 2010, a total of 19 patients suspected of having PBS/IC; 13 women and 6 men (mean 70.6±8.9 years, range: 52–83) were included into this prospective study. The suspected symptoms of PBS/IC were followed by the criteria of database studies on IC provided by the National Institute of Diabetes and Digestive and Kidney Diseases, in 1987; urinary frequency, urgency, chronic pelvic pain, pressure, or discomfort perceived to be related to the bladder accompanied by persistent urge to void or frequency. All symptoms continued for six months or longer, in the absence of other pathology (e.g., urinary tract infection, bladder cancer and stone). All patients had failed multiple standard therapies for PBS/IC prior to the enrollment into this study. Each patient was first evaluated by using a flexible cystoscope with WLI. Then, the cystoscope was switched to NBI view by putting a button on the control section of scope. NBI was always performed after WLI. One same urologist performed all the examinations with WLI and NBI. The urologist estimated the presence or absence of the ulcerative lesions (Hunner's lesions), counted and recorded the number and location of Hunner's lesions or suspect areas on a bladder diagram. In this study, we did not estimate the size and expanse of the Hunner's lesions. After the endoscopic examination of the bladder with WLI and NBI, hydrodistension was added in all cases to estimate whether the Hunner's lesions would be changed into glomerulations or not, by keeping the irrigation bag below 80 cm height or limiting the amount of irrigation fluid instilled into the full bladder. These procedures were carried out under spinal anesthesia in 9 patients and under local anesthesia (intravesical 30ml 4% lidocaine) in 8 patients on an outpatient basis. In the 9 patients carried out under general or spinal anesthesia, Hunner's lesions identified by NBI were biopsied and specimens obtained were examined by an institutional pathologist. After the biopsy, all Hunner's lesions and suspect areas identified by NBI were endoscopically fulgurated under NBI observation (NBI-assisted TUF).

Treatment outcomes of NBI-assisted TUF were estimated at 1 month postoperatively, and then every 3 months, or if symptoms recurred. The primary outcomes of the treatment were preoperative and postoperative visual analogue pain score (VAS), O'Leary and Sant Symptom and Problem Questionnaire, and overall patient satisfaction on a scale of 0 to 6 (delighted, pleased mostly, satisfied, mixed mostly, unhappy, unhappy terrible) and bladder biopsy pathology reports. Full informed consent was acquired from all patients.

### Results

Two of 17 patients (10.5%) were ruled out because no Hunner's lesions were detected by both WLI and NBI and no petechial hemorrhage or glomerulations were observed after hydrodistension. Among the residual 17 patients diagnosed as having PBS/IC, 12 patients (70.5%) were found to have Hunner's lesions by conventional WLI, which were also recognized distinctly as capillary-rich brownish areas when observed by using NBI (100% accuracy). Thirteen patients (76.5%) were found to have NBI-positive areas without Hunner's lesions. In one patient (5.9%), only NBI could detect Hunner's lesions. The mean ± standard deviation (range) number of Hunner's ulcers of each patients by using WLI and NBI were 2.4±1.4 (0–4) and 3.5±2.2 (0–7), respectively. After subsequent hydrodistension, all Hunner's lesions detected by NBI were changed into glomerulations and/or petechial hemorrhages. In the remaining 4 patients whom NBI did not detect Hunner's lesions prior to hydrodistension, glomerulations and/or petechial hemorrhages were demonstrated from normal bladder mucosa after hydrodistension.

Biopsy and NBI-assisted TUF were carried out in the 9 patients under spinal anesthesia. Symptom and Problem index and VAS after surgery were significantly reduced ( $p < 0.05$ ; Table) and all but two (22.2%) had no recurrence of PBS/IC related symptoms or pain after a mean follow up of 14.2 months.

### Interpretation of results

PBS/IC can be classified into Hunner's lesions/ulcers (ulcerative subtype) and non-ulcer disease (non-ulcerative subtype). The detection rate of Hunner's lesions by WLI is 10 to 50%. Then, Hunner's lesions could easily be overlooked or misdiagnosed as carcinoma in situ by WLI. NBI is an optical image enhancement technique designed for endoscopy to enhance the contrast between mucosal surfaces and microvascular structures without the use of dyes. This technique is based on the phenomenon that the depth of light penetration into the mucosa increases with increasing wavelength. Since these specific wavelengths are strongly absorbed by haemoglobin, the vascular structures appear dark brown or green against a pink or white mucosal background. Because Hunner's lesions usually consist of small capillaries and submucosal vessels, it is speculated that they may be well visualized and appeared as dark brownish or green areas. T. Ueda demonstrated that NBI makes it possible to easily detect Hunner's lesions. Our results demonstrated the same results. In our study, WLI overlooked about 30% of Hunner's lesions.

The residual or overlooked Hunner's lesions may consequently lead to early recurrence of PBS/IC symptoms, in up to 45% of patients. Transurethral endoscopic resection (TUR) or TUF of the Hunner's lesions is applicable in ulcerative subtype of IC/PBS, which leads to symptomatic resolution for one year or longer in about half of patients. Because NBI makes it possible to easily detect Hunner's lesions, it is speculated that NBI-assisted TUF would improve TUR/TUF quality for PBS/IC patients with Hunner's lesions. Our results proved the speculation.

Concluding message

Our study demonstrated that NBI was an accurate diagnostic new tool for ulcerative subtype of PBS/IC without the need for hydrodistention and that NBI-assisted TUF was effective in relieving symptoms in PBS/IC patients with Hunner's lesions. We believe NBI may be considered an effective diagnosis and treatment tool for patients with suspected symptoms of PBS/IC.

Table	preoperative	postoperative (4ws)	p-value
Symptom index	16.0+/-2.4 (13-20)	8.4+/-1.9 (5-11)	<0.05
Problem index	13.0+/-3.5 (8-16)	2.7+/-1.1 (1-4)	<0.05
VAS	7.6+/-2.3 (4-10)	2.3+/-0.70 (1-3)	<0.05

Fig. a; typical Hunner's lesion  
WLI (right) and NBI (left)

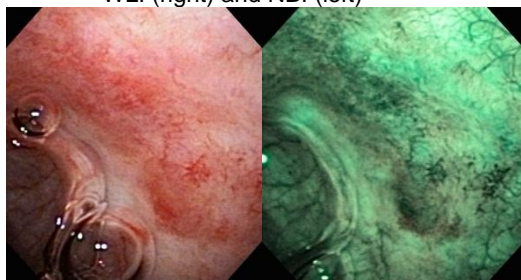
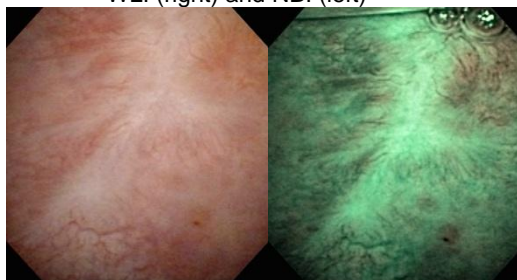

Fig. b; atypical Hunner's lesion  
WLI (right) and NBI (left)



<i>Specify source of funding or grant</i>	none
<i>Is this a clinical trial?</i>	Yes
<i>Is this study registered in a public clinical trials registry?</i>	No
<i>Is this a Randomised Controlled Trial (RCT)?</i>	No
<i>What were the subjects in the study?</i>	HUMAN
<i>Was this study approved by an ethics committee?</i>	No
<i>This study did not require ethics committee approval because</i>	this study is a small pilot study.
<i>Was the Declaration of Helsinki followed?</i>	Yes
<i>Was informed consent obtained from the patients?</i>	Yes