

SHORT AND MID-TERM OUTCOME OF ROBOTIC MESH SACROCOLPOPEXY FOR THE REPAIR OF PELVIC ORGAN PROLAPSE WITH ABSORBABLE SUTURES

Hypothesis / aims of study

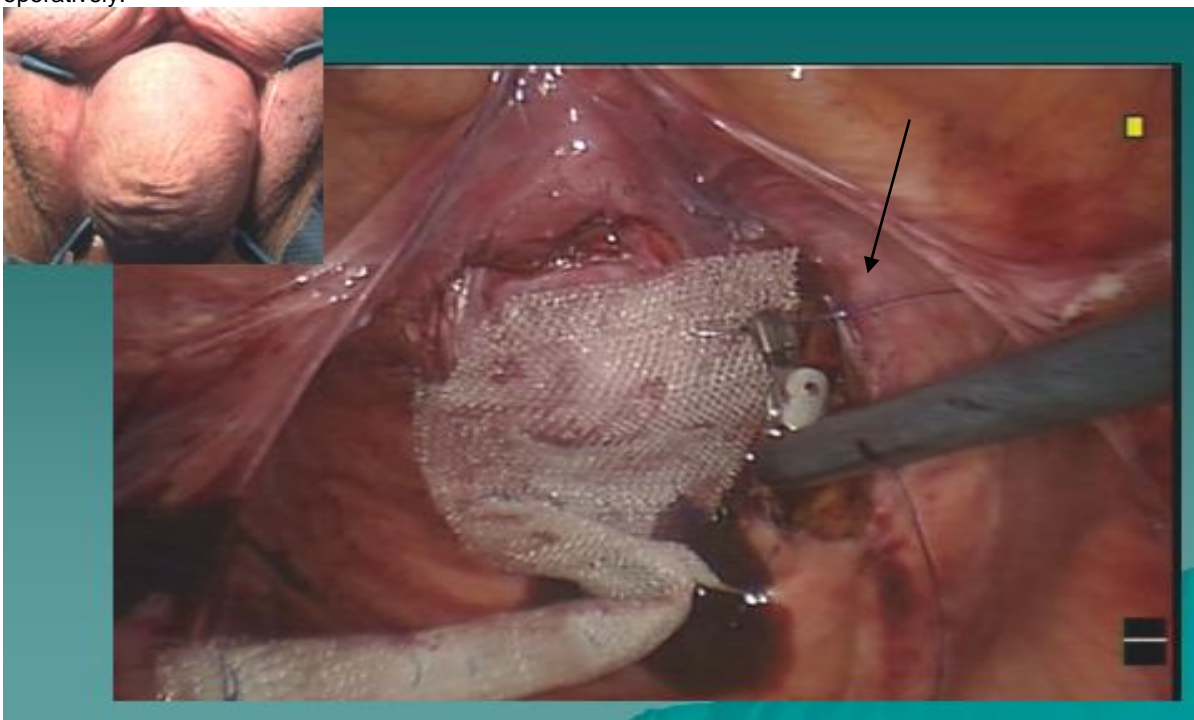
To review the outcome of robotic mesh sacrocolpopexy (RMS) in women with symptomatic pelvic organ prolapse (POP) using absorbable suture to anchor the mesh to the vaginal wall.

Study design, materials and methods

A retrospective chart review was performed to analyze the anatomical outcome of RMS with absorbable sutures in the treatment of symptomatic POP. All patients underwent history, review of prior pelvic surgeries, and physical examination including pelvic examination using the POP-Q system. In cases of bladder involvement, a standing voiding cystourethrogram and urodynamic testing with vaginal pack reduction of the prolapse was also performed (1). Pelvic MRI was ordered selectively in cases of POP recurrence. Indication for RMS over vaginal repair surgery was based on patient preference along with BMI (≤ 30), absence of major prior abdominal surgeries, age less than 80, or desire to retain sexual activity. RMS was done with Marlex® mesh and absorbable 2-0 polyglactin sutures to anchor the mesh to the vaginal walls and apex. Patients were followed post-operatively at 6 weeks, 6 months, 12 months and yearly thereafter for evidence of immediate or delayed complications, and for evaluation of the durability of the repair. The Urogenital Distress Inventory (UDI-6), Incontinence Impact Questionnaire (IIQ-7) and a one global quality of life (QoL) questionnaire based on a visual analogue scale (range 0 excellent to 10 terrible) were obtained routinely at all office visits before and after surgery.

Results

From January 2008 to August 2010, a total of 26 patients with symptomatic POP underwent RMS and had at least 6 months follow-up. Concomitant procedure was done in 5, including supracervical hysterectomy, extensive lysis of adhesions, fulguration of trigonitis with urethral dilation and excision of breast melanoma, fulguration of trigonitis alone, and excision of a urethral caruncle. Mean patient age was 65 years (37-79). Mean EBL was 81ml (0-375). Mean operating room time including anesthesia induction and wake up was 4.8 hours (3.5-6.5). Mean pre-operative C-point was -1.5 (-4 to 1) with mean post-operative C-point of 10 (-12 to -8) ($p < 0.0001$). There were 4 intra-operative complications all of which were vaginotomies that were oversewn and no patients required conversion to open. Mean duration of follow-up was 16 months (6-36). Two patients have undergone POP re-operation, one for distal rectocele and one for distal cystocele. No patients have required reoperation for vault prolapse. One patient developed apical mesh erosion noted at her 6 month follow up and returned to the operating room for local vaginal excision. In addition, one patient developed a port site hernia and has undergone surgical repair. A significant improvement in quality of life was noted following surgery based on a QoL improvement of 3.7 (5.14 to 1.45, $p = 0.002$), and IIQ-7 of 5.8 (6.75 to 0.95, $p = 0.04$). UDI-6 mean improvement was 1.9 (5 to 3.14) ($p = 0.09$). No new onset dyspareunia has been reported so far, and all sexually active patients pre-operatively have remained sexually active post-operatively.



Interpretation of results

Robotic procedures for prolapse repair often provide limited access to the vagina because of the need to use a clamp (EEA probe) or other long molding instrument during prolapse compartment dissection as well as the location of the robot between

the legs during traditional docking. When the mesh is secured to the anterior, posterior and/or apical segments of the vagina, it is not easy to determine if the suture has transfixed the thin vaginal wall. Concern for secondary mesh erosion has been higher with transfixing non-absorbable sutures.[2] Solutions to avoid this complication have been side docking the robot to allow easier access to the vaginal cavity during the RMS as well as the use of absorbable sutures to anchor the mesh. However, the use of absorbable sutures has been considered anathema by those adhering to the tenet of always fixing the mesh with non-absorbable sutures, the fear being that such an anchoring technique would fail and POP would recur. Because Marlex® mesh offers rapid and strong tissue integration in between the weaves of the mesh; we felt that this tenet was possibly not that critical. This series indicates that the use of absorbable sutures with a fairly slow decay rate, such as polyglactin, is safe and efficacious for RMS while obviating the concerns of using non-absorbable suture.

Concluding message

Based on our experience, RMS can be done with absorbable sutures without compromising the anatomical repair in women with symptomatic prolapse that are candidates for robotic surgery. Improvement in quality of life and lack of new onset dyspareunia are also important secondary findings in this follow up of patients undergoing RMS.

References

1. Gilleran, J et al. BJU Int 97: 292-5, 2006
2. Shepherd JP, et al. Female Pelvic Medicine & Reconstructive Surgery 16:229-233, 2010.

Specify source of funding or grant

none

Is this a clinical trial?

No

What were the subjects in the study?

NONE
