

CAN BLADDER OUTLET OBSTRUCTION BE DIAGNOSED FROM THE URETHRAL CROSS-SECTIONAL AREA ESTIMATED BY ULTRASOUND IMAGING?

Hypothesis / aims of study

Several non-invasive imaging techniques exist that propose a method to diagnose bladder outlet obstruction. Some of these use the cross-sectional area of the urethra as a parameter. The area is obtained either by direct measurement with the aid of transrectal ultrasound [1] or by indirect measurement using transperineal Doppler ultrasound [2].

In theory, the resistance of a collapsible tube depends on the cross-sectional area of the tube and the pressure that is required to keep the tube open. The non-invasive imaging techniques referenced above, however, do not measure the latter. We hypothesized that therefore it might be problematic to diagnose Bladder Outlet Obstruction (BOO) on the basis of cross-sectional area alone. As this is somewhat counterintuitive we sought for experimental verification of the extent to which the urethral cross-sectional area can be used to diagnose BOO. Our second aim was to assess whether or not the urinary flow rate provides additional information for the diagnosis.

Study design, materials and methods

The hypothesis was tested in an experimental model of the bladder outlet system (see Fig. 1). Polyvinyl Alcohol (PVA) cryogel was used to make a soft, tissue mimicking phantom representing the lower urinary tract of a male. To create an obstruction, the PVA tube was enclosed in a watertight box maintained at a variable pressure p_{prostate} (range 0 – 200 cm H₂O). The flow through the model was generated by a variable head of water p_{head} (range 40 – 80 cm H₂O). The detrusor pressure p_{det} was modelled by the pressure-drop p_1 - p_2 over the model urethra. In this way, pressure drops in the tubing between the pressure head container and the model urethra, and between the model urethra and the outflow orifice were excluded.

For a large number of combinations of p_{head} and p_{prostate} , the cross-sectional area of the model urethra was measured on B-mode ultrasound images (Pro Focus UltraView 800 with a type 8670 transducer operating at 12 MHz, BK Medical). The corresponding flow rate Q was measured with a rotating-disc uroflowmeter. The BOO index (BOOI) given by p_{det} (in cm H₂O) minus $2 \cdot Q$ (in ml/s) was calculated and used as the golden standard for BOO.

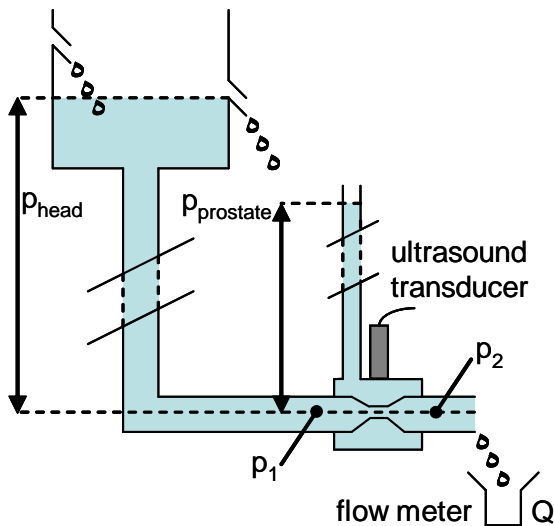


Fig. 1. Schematic drawing of the physical model of the bladder outlet system.

Results

For each measured lumen area the corresponding values for BOOI and Q are depicted in Fig. 2a and 2b, respectively.

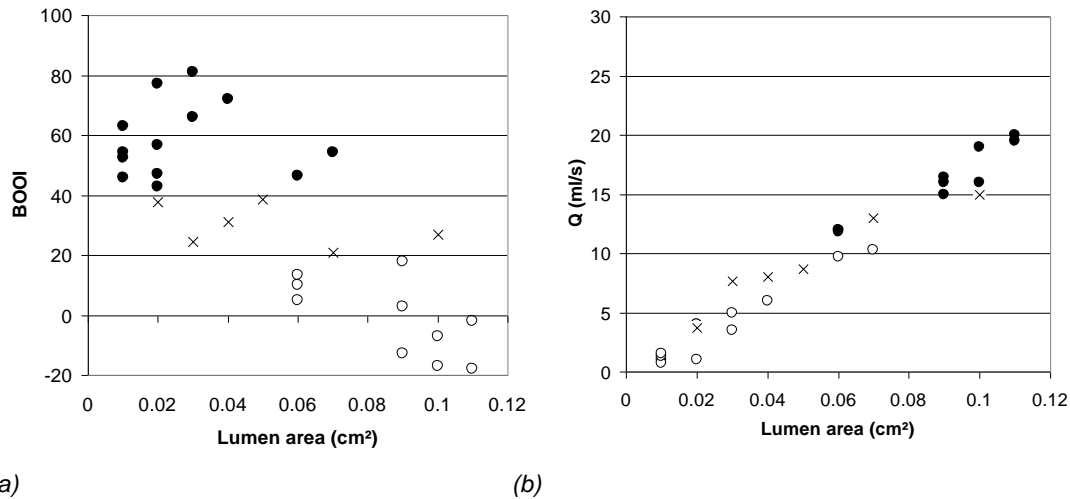


Fig. 2. (a) BOOI as a function of the lumen area. (b) Flow rate Q as a function of the lumen area. Legend: \circ unobstructed, \times equivocal, or \bullet obstructed situation according to the BOOI.

Interpretation of results

For a single lumen area, many BOOI values were found (Fig. 2a). The range of values found was mainly limited by the range of values for p_{prostate} and p_{head} used in this study. The range was large enough to demonstrate that for a given lumen area (for instance 0.06 cm^2) both unobstructed (BOOI < 20) and obstructed (BOOI > 40) situations existed. This can be explained as follows: the pressure required to drive a certain flow rate through the urethra depends on the cross-sectional area and on its stiffness. A stiff urethra or a urethra with a compressive obstruction requires more pressure to open up to the same cross-sectional area, than a more flexible urethra. Thus, at the same cross-sectional area, a stiffer urethra offers more resistance to flow.

In the literature it has been shown that Q_{max} has a (too) limited power for diagnosing BOO [3]. In our model, we found that there is a direct relationship between the flow rate Q and the lumen area (Fig. 2b). Therefore, we think that a combined measurement of lumen area and Q_{max} will not improve the power for diagnosing BOO. This can be appreciated in Fig. 2b by the fact that for a lumen area of 0.06 cm^2 and a flow rate of approximately 11 ml/s both unobstructed (\circ) and obstructed (\bullet) situations were found. The findings in this study support our hypothesis that for the same urethral cross-sectional area in patients, BOOI can be different depending on the stiffness of the urethra and of the surrounding tissue [2].

Concluding message

In our model of a flexible urethra, a single value for the cross-sectional area could accommodate both unobstructed and obstructed flow, according to the ICS nomogram. We expect this to happen in patients as well. Therefore, bladder outlet obstruction cannot be diagnosed from the urethral cross-sectional area and/or flow rate during voiding.

References

1. H. Jansen, R. van Mastrigt, and M. Kranse. Transrectal ultrasound of the prostatic urethra related to urodynamically assessed urethral resistance. A pilotstudy. *Urol Res* 22:147-150, 1994.
2. H. Ozawa, M.B. Chancellor, Y.Y. Ding, Y. Nasu, T. Yokoyama, and H. Kumon. Noninvasive urodynamic evaluation of bladder outlet obstruction using Doppler ultrasonography. *Urology* 56(3), 2000.
3. T. Idzenga, J.J.M. Pel, R. van Mastrigt. Accuracy of Maximum Flow Rate for Diagnosing Bladder Outlet Obstruction Can Be Estimated From the ICS Nomogram. *Neurourology and Urodynamics* 27:97-98, 2008.

Disclosures

Funding: BK Medical supported our research by lending an ultrasound system (Pro Focus UltraView 800) and transducers.
Clinical Trial: No **Subjects:** NONE