

## SURGICAL REDUCTION OF THE LEVATOR HIATUS

### Hypothesis / aims of study:

Excessive distensibility of the levator hiatus is strongly associated with female pelvic organ prolapse (FPOP) (1) and recurrence of prolapse after Anterior Compartment reconstruction. A larger hiatus likely implies higher mechanical stresses, most importantly during wound healing, heightening the risk of failure. We have designed a surgical procedure to achieve permanent reduction of hiatal dimensions.

### Study design, materials and methods:

We enrolled 100 patients in this Phase I prospective surgical pilot study. Entry criteria were 1) patient requiring prolapse repair, and 2) hiatal ballooning of  $\geq 35$  cm<sup>2</sup>. After completion of standard prolapse repair (+/- mesh depending on the surgeon's preferences), a post-anal tunnel was created via two 2 cm incisions 3-4 cm posterior and lateral to the anus. A 3 cm wide strip of polypropylene mesh was cut diagonally from a 6x6 inch patch of polypropylene. This strip was placed through the postanal tunnel and retrieved by a curved Stamey or Pereyra needle passed through the obturator foramen, through a 2 cm groin incision. After retrieval the distal end of the strip was anchored to the inferior surface of the inferior pubic ramus using delayed absorbable sutures, after tensioning to reduce the sum of genital hiatus and perineal body (ICS POP-Q gh+pb) to 7 cm. Patients were followed up 3, 6 and 12 months after the procedure, with an interview, ICS POP-Q assessment and pelvic floor ultrasound. Hiatal area on Valsalva as the primary outcome measure and pelvic organ descent as secondary outcome measures were determined offline in datasets obtained using Voluson 730 expert systems with RAB 8-4 Mhz transducers (2).

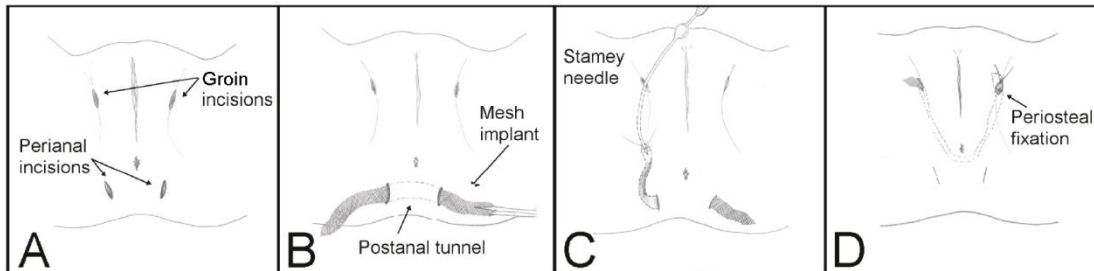


Fig. 1: Puborectalis sling procedure. A shows the incisions, B insertion of the implant, C its retrieval by curved needle, and D anchoring of the implant to the inferior pubic ramus.

### Results:

Mean age of study participants was 61 (29-88) years. Mean body mass index was 29 (17-44). All except one were vaginally parous, 22/100 reported a previous vaginal operative delivery. 48/100 had previously had a hysterectomy, 35 an incontinence or prolapse procedure. Patients suffered from symptoms of prolapse (n=100), stress incontinence (n=57), urge incontinence (n=70), frequency (n=35), nocturia (n=34) and symptoms of voiding dysfunction (n= 47). All had a symptomatic prolapse ICS POP-Q stage  $\geq 2$  (stage 3+, n=73) on clinical assessment (cystocele, (n=83), uterine prolapse (n=33), rectocele or recto-enterocele (n=70). An avulsion was diagnosed in 62/100 (27 bilateral). Mean hiatal area on Valsalva was 44 (35- 63) cm<sup>2</sup>, with 64/100 showing severe ballooning  $>40$  cm<sup>2</sup>.

To date, 93 patients have undergone a puborectalis sling. Concomitantly, we performed 36 vaginal hysterectomies, 56 vault suspension procedures, 70 anterior repairs (31 with mesh augmentation), 67 posterior repairs and 29 suburethral slings. There were no cases of vaginal or rectal/ anal perforation due to the needle passage, and no other major intraoperative complications due to the puborectalis sling. Minor technical issues included two cases of inadvertent infrapubic passage of the needle and several mesh dislodgments from the needle on mesh retrieval, necessitating additional needle passes. In one case, a concomitant sacrospinous colpopexy resulted in perforation of the rectal ampulla, recognised intraoperatively and followed by an uneventful recovery after suture removal. Postoperatively we observed one case each of potential compression of the inferior rectal nerve and of stool impaction one week after surgery. Both resolved without further sequelae. In one case, a wound infection affected the implant. It was removed on Day 9 through one of the perianal wounds, after cutting of anchoring sutures on both sides. In another case, we had to release the implant at its suturing site on the inferior pubic ramus due to marked de novo symptoms of obstructed defecation.

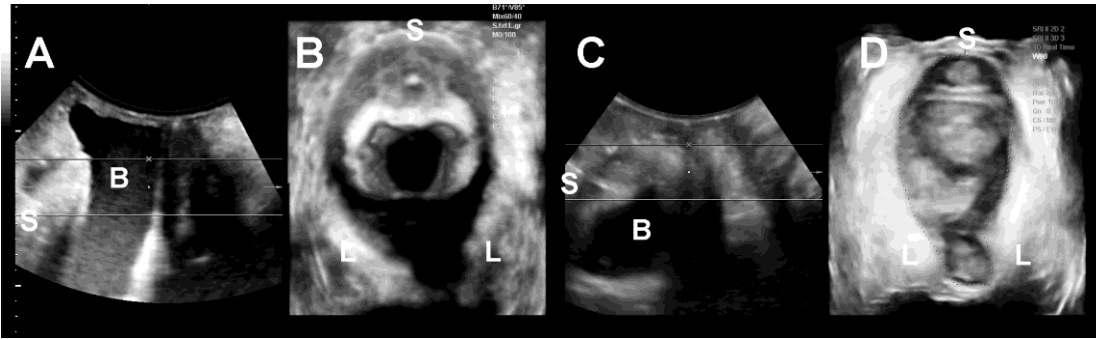


Figure 2: Hiatal reduction from 35 to 22 cm<sup>2</sup> three months after insertion of a puborectalis sling. Midsagittal (A) and axial (B) view on Valsalva before anterior repair, transobturator sling and sacrospinous fixation; midsagittal (C) and axial (D) view on Valsalva 3 months after the procedure. S= symphysis pubis, B= bladder, L= levator ani.

We report results at 3,6 and 12 months (see Table). There was a highly significant reduction in hiatal dimensions which was sustained at 6 and 12 months. We observed no erosion of the sling implant into vagina or viscerae.

Parameter	Preoperative N=100	3 m postop N= 70	6 m postop N=56	12 m postop N=19
Subjective satisfaction		64/70 (91%)	45/56 (80%)	14/19 (74%)
Subj. improved/ cured		64/70 (91%)	53/56 (95%)	18/19 (95%)
Prolapse symptoms	100	14/70 (20%)	15/56 (27%)	7/19 (37%)
ICS POP-Q stage $\geq 2$ in any compartment	100	46/70 (66%)	41/56 (73%)	15/19 (79%)
Significant prolapse on Ultrasound(3)*	100	37/70 (53%)	32/56 (57%)	11/19 (58%)
Hiatal area on Valsalva (cm <sup>2</sup> , SD)	43.9 (35- 63)	31.6 (18.1- 44.7)**	32.0 (18.1- 43.7)**	32.4 (24.4- 45.5)**

Table: Subjective and objective outcomes after prolapse repair with puborectalis sling at 3, 6 and 12 months. \*Cystocele  $\geq 10$  mm below symphysis pubis (SP), enterocele  $\geq$  the level of the SP, rectal ampulla  $\geq 15$  mm below SP; \*\*Reductions in hiatal area all  $P < 0.001$  at 3,6, and 12 months.

#### Interpretation of results:

This pilot trial was designed to determine whether it is possible to surgically reduce the levator hiatus with acceptable intra- and postoperative complication rates. We have provided proof of this concept. It appears feasible to reduce hiatal dimensions with a mesh implant placed through the ischioanal fossa, with an average change from 44 to 32 cm<sup>2</sup> sustained to one year, with acceptable intra- and postoperative complication rates.

#### Concluding message:

The 'Puborectalis sling' procedure is a minimally invasive technique that results in a reduction in the size of the levator hiatus by about 25-30%. This reduction seems to be sustained to 1 year. We are about to begin a multicentre randomised controlled trial to determine the effect of hiatal reduction surgery on prolapse recurrence rates.

#### References

1. Dietz HP, Shek KL, De Leon J, Steensma A: Ballooning of the levator hiatus. *Ultrasound Obstet Gynaecol* 2008; 31: 676-680
2. Dietz HP. Pelvic Floor Ultrasound in incontinence: What's in it for the surgeon? *Int Urogynecol J* 2011; 22 (9): 1085-1097
3. Dietz HP, Lekskulchai O. Ultrasound assessment of pelvic organ prolapse: the relationship between prolapse severity and symptoms. *Ultrasound Obstet Gynecol* 2007; 29: 688-691

#### Disclosures

**Funding:** Nil **Clinical Trial:** Yes **Public Registry:** No **RCT:** No **Subjects:** HUMAN **Ethics Committee:** Nepean Blue Mountains LHD Human Research Ethics Committee **Helsinki:** Yes **Informed Consent:** Yes