

### SUPRAPUBIC TUBE PLACEMENT RELATED BOWEL INJURY: PROPOSED GUIDELINES FOR OPEN PLACEMENT

Hypothesis / aims of study

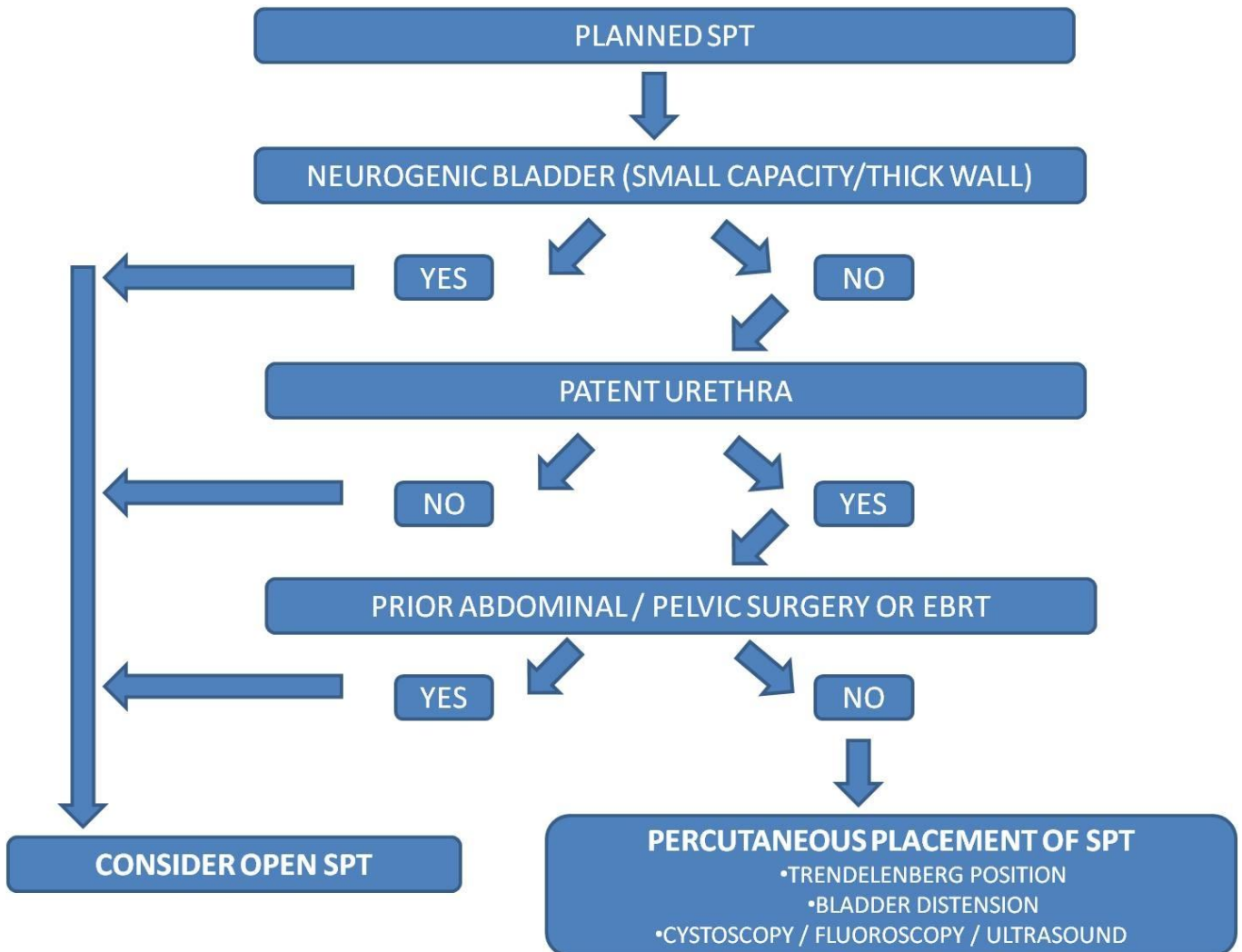
Suprapubic tube (SPT) placement is a commonly performed procedure for urinary drainage in select patient populations. The development of minimally invasive alternatives has allowed SPTs to be placed at the bedside, in the office and emergency room settings in lieu of the operating room. Despite the simplicity of placement, proper patient selection is important in decreasing associated risk. Over a one year period we had 5 cases of SPT-related bowel injury and reviewed the literature to determine identifiable risk factors for SPT-related bowel injury.

Study design, materials and methods

A literature review was performed with PubMed using the terms: suprapubic tube, bowel injury and complication of suprapubic tube. Articles reporting percutaneous SPT placement related bowel injury were selected. Also, we reviewed 5 recent cases at our institution. Data from the articles and our 5 cases was extracted to determine the technique of SPT placement utilized, underlying risk factors and the nature of the bowel injury.

Results

18 papers reported 28 cases of bowel injury as a result of percutaneous SPT placement, 8 cases of which were excluded for insufficient data. The 5 cases at our institution were included for analysis. Small capacity or thick walled neurogenic bladders (4/25, 16%), prior abdominal surgery (13/25, 52%) and external beam radiation (EBRT) (6/25, 24%) were associated with bowel injury during SPT placement. Bowel injury had a bimodal presentation, at initial placement (14/25, 56%) and at or following the initial catheter change (11/25, 44%). Of these 25 patients, 3 had Clavien class II complications, 20 Clavien class IIIb complications and 2 Clavien class V complications.



### Interpretation of result

There are several limitations of our study. Cases of SPT related bowel injury may be under-reported in the literature, as reflected by the fact that we were only able to identify 38 cases reported in the literature over the past 30 years. The study is retrospective and looks only at reported cases of SPT-related bowel injury and not at the number of SPTs placed. Lastly, there were multiple percutaneous techniques utilized in the case reports and series reviewed. However, the morbidity and potential mortality of SPT-related bowel injury underscores the need for identification of those at risk.

### Concluding message

Based on a comprehensive review of the literature as well as our experience we advocate strong consideration of open SPT placement in (1) patients with thick walled neurogenic bladders with small capacity, (2) patients without a patent urethra, (3) those individuals with prior abdominal surgery, intraperitoneal surgery or abdominal/pelvic EBRT. Furthermore, in those patients undergoing percutaneous placement of a SPT, we recommend the following: (1) absence of the aforementioned criteria for open SPT placement, (2) use of Trendelenburg position, (3) confirmation of bladder distension by palpation, bladder scan/ultrasound, or direct filling, and (4) radiographic guidance with ultrasound or fluoroscopy. We developed an algorithm reflecting these recommendations

### References

1. Ahluwalia RS, Johal N, Kouriefs C et al. The surgical risk of suprapubic catheter insertion and long-term sequelae. Ann R Coll Surg Engl; 88: 210, 2006.
2. Dindo D, Demartines N, Clavien PA. Classification of surgical complications: a new proposal with evaluation in a cohort of 6336 patients and results of a survey. Ann Surg, 240: 2005, 2004.
3. Aguilera PA, Choi T, Durham BA. Ultrasound-guided suprapubic cystostomy catheter placement in the emergency department. J Emerg Med, 26: 319, 2002.

### Disclosures

**Funding:** No funding **Clinical Trial:** No **Subjects:** HUMAN **Ethics not Req'd:** retrospective review of cases. received IRB approval **Helsinki:** Yes **Informed Consent:** No