

LOWER URINARY TRACT SYMPTOMS AFTER HIGH INTENSITY FOCUSED ULTRASOUNDS (HIFU) TREATMENT FOR LOCALIZED PROSTATE CANCER. 5 YEAR EXPERIENCE OF FIRST SPANISH SERIES.

Hypothesis / aims of study

The use of minimally invasive ablative therapies, specially in patients with associated morbidity, attempt to reduce treatment burden offering similar oncological effectiveness to standard treatment. Probably High Intensity Focused Ultrasound (HIFU) allows a middle ground between active surveillance and radical treatments in these patients with organ-confined prostate cancer.

Aim of this study was to evaluate prevalence and management of lower urinary tract symptoms (LUTS) in patients treated with HIFU

Study design, materials and methods

From May 2007 up to now, we performed HIFU therapy (sonoblate 500) to 34 patients with localised prostate cancer, diagnosed by TRUS-guided prostate biopsy and magnetic resonance imaging (MRI). We excluded patients with previous rectal surgery or anal pathologies, rectal or urinary fistula, patients allergic to latex, patients with intraprostatic calcification > 1 cm. or many microcalcifications and also patients with more than 4 cm of antero-posterior prostatic diameter. Follow-up included PSA quarterly measurement for 1 year and MRI at first, third and ninth month. Associated morbidity overcoat included precedents of acute heart attack, carriers of pacemaker or anti-coagulated patients.

Results

Mean age of our patients was 67'33 years. Mean PSA level preoperative was 7,68 ng/mL, Gleason's score was < 7 in 29 patients and 7 in 5 patients. 28 had D'Amico low risk disease and 6 intermediate risk. Mean prostate volume was 28'61 cm³. Mean follow-up period was 37,23 months. The mean postoperative suprapubic catheterization time was 16 days. The most common urinary symptoms were: 3 patients postoperative haematuria, 4 patients developed symptomatic urinary tract infections, and 6 patients complained urinary urgency at their first visit, that wasn't reported at the third month follow-up visit. Stress incontinence was seen in 8 patients at the third month follow-up visit; at the next visit only 5 patients reported minor stress incontinence (drops). At one year follow-up visit all patients were continent and it was maintained during the total follow up period. Two patients required transurethral resection of the prostate because of acute obstruction. There wasn't prostate carcinoma in the biopsy in these cases. We present PSA kinetics during 5 years follow up attached.

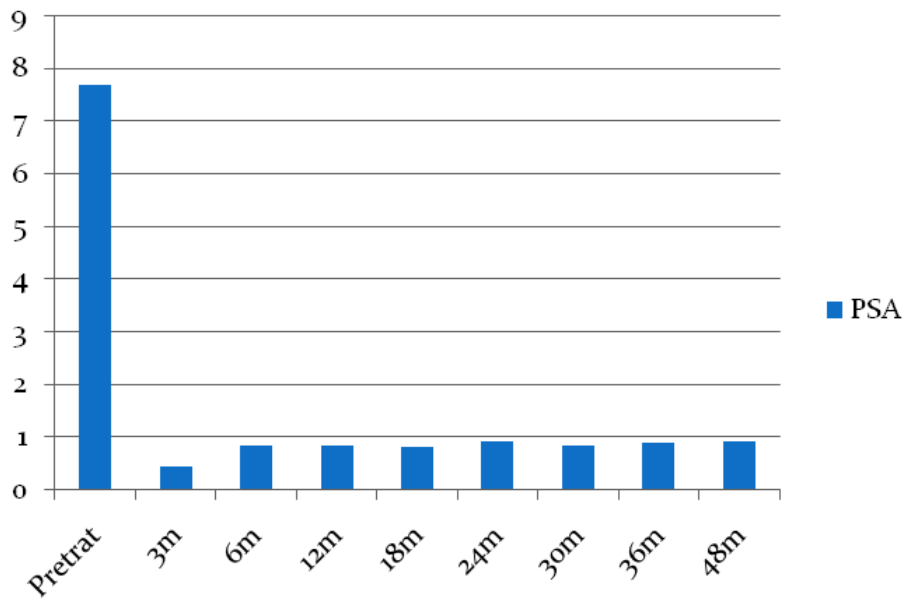
Interpretation of results

Minimally invasive ablative therapies allows a reduced prevalence of lower urinary tract symptoms (LUTS) in localized prostate cancer patients treated with HIFU even regarding the elderly treated population. We recommend the intraoperative use of steroids and maintenance of antibiotics in the early postoperative period

Concluding message

HIFU short-term outcomes are promising for the treatment of localized prostate cancer. It's a minimally invasive treatment with a low rate of complications. Longer-term follow-up studies and more cases are needed to obtain evidence based oncology results

Cinética PSA



References

1. Shoji S, Nakano M, Nagata Y, Usui Y, Terachi T, Uchida T. "Quality of life following high-intensity focused ultrasound for the treatment of localized prostate cancer: a prospective study".
2. Ahmed H, Emberton M. "Is focal therapy the future for prostate cancer?".
3. Blana A, Murat FJ, Walter B. First analysis of the long term results with transrectal HIFU in patients with localized prostate cancer.

Disclosures

Funding: None **Clinical Trial:** No **Subjects:** HUMAN **Ethics not Req'd:** Routine clinical practice **Helsinki:** Yes **Informed Consent:** Yes