

## ARTERIAL AND VENOUS MACRO VASCULAR ANATOMY OF THE MINIATURE PIG URINARY BLADDER

### Hypothesis / Aims of study

Although pig bladders are used extensively for research purposes, the specific anatomical details of the arterial and venous supply are not completely understood. An extensive internet search failed to reveal any published work on the subject. The aim of this study was to document and describe the macro vascular anatomy of the arterial and venous systems of the miniature pig urinary bladder.

### Study design, materials and methods

12 adult mini pigs (8 females and 4 males) aged between 6 months to 1 year, which had been euthanized by exsanguination, were dissected. The structures of their arterial and venous trees were recorded.

In three of the specimens, after cannulating the abdominal aorta and inferior vena cava, vascular corrosion casts were made using Mercorex resin (8ml Mercorex, 2ml Methyl methacrylate catalyst and 0.3ml catalyst). The vasculature was perfused with Mercorex. This usually set within 10 minutes. The specimens were immersed in warm (50<sup>o</sup> C) water overnight. The tissues were then removed using alternating rinses of 5% KOH and distilled water.

In 2 specimens, arteriograms were made using 10 ml of Niopam (40.8% w/v Iopamidol) each.

### Results

All the pigs dissected, were found to have similar anatomy. Morphologically, the pig bladder is quite similar to the human bladder. The major features of the vascular tree were;

1. Abdominal Aorta: After giving off the paired external iliac arteries, at the level of L4- L5 vertebra, the aorta ends as a single internal iliac artery. 2. At the trifurcation of the internal and external iliac arteries, on the ventral aspect, the median sacral artery emerges and runs distally. 3. The internal iliac artery divides into the umbilical and the internal pudendal arteries. The dome of the bladder is supplied mainly by several small branches from the umbilical arteries, which are more prominent and longer than in humans. The rest of the bladder and proximal urethra is supplied by vesical branches from the internal pudendal artery, the prostatic artery in the male and the vaginal artery in the female. The distal urethra is supplied by the urethral branch of the internal pudendal artery.

This arrangement was confirmed by the arterial corrosion casts and the arteriograms.

#### External Iliac artery

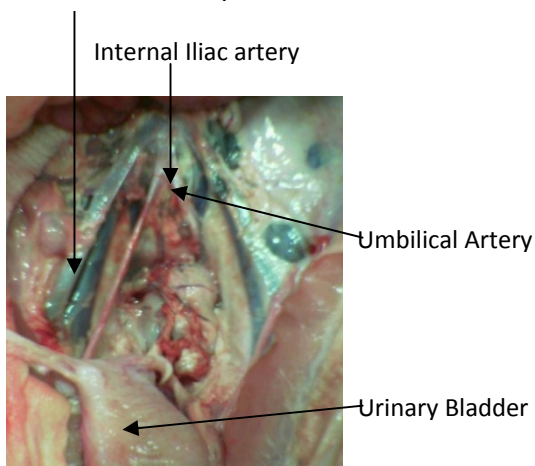


Figure 1. Arterial Anatomy

#### Internal Pudendal Artery

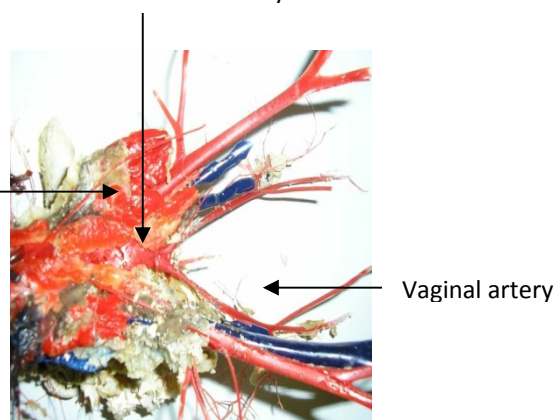


Figure 2. Arterial Corrosion Cast

**Venous drainage:** The veins form a plexus on the inferolateral surface of the urinary bladder. Three to five tributaries emerge from the bladder, run in the lateral vesical ligament, drain into the Vaginal / Prostatic vein and ultimately join the internal iliac vein. In addition to this the fundus of the bladder is drained by 4 to 6 tributaries which drain into the gonadal veins.

Corrosion casts of the venous tree and Venograms could not be made due to the poor perfusion of the venous vasculature as well as abundance of valves.

#### Internal Iliac vein



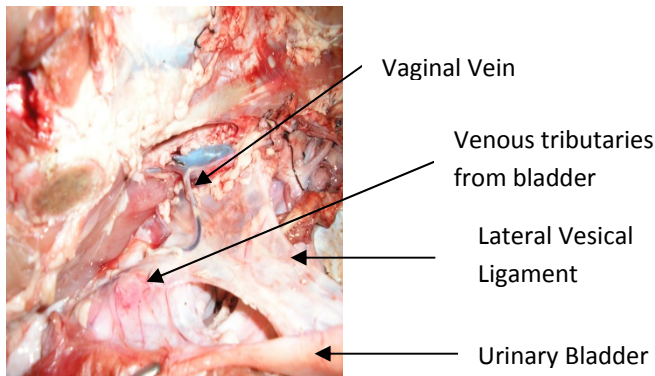


Figure 3. Venous Anatomy

Interpretation of results

Pig bladders are sufficiently similar to human bladders to make them a good model for experimental studies. There are significant differences in the vascular supply as compared to human bladders. 1. There is only one internal iliac artery in pigs as compared to paired vessels in humans. 2. The fundus is supplied by several small branches from the umbilical instead of a single superior vesical artery. 3. There is no inferior vesical artery; instead several small branches from the internal pudendal artery supply the lower half of the bladder and the proximal urethra. 4. The fundus of the bladder is drained by tributaries to the gonadal veins.

Concluding message

By this study we were able to successfully define the macrovascular anatomy of the arterial and venous trees of the miniature pig urinary bladder. A better understanding of vascular anatomy will aid in the development of models for physiological and pharmacological studies using whole pig bladders. In addition, it will allow comparison studies with human bladders relevant to patho-physiological understanding and development of surgical techniques

**FUNDING:** None

**ANIMAL SUBJECTS:** This study did not follow the guidelines for care and use of laboratory animals because No ethical approval was needed for this study, as the specimens had been sacrificed following other studies and were intended for dissection at the Anatomy department (Comparative morphology centre), before being disposed.