

BALLOONING: HOW TO DEFINE ABNORMAL DISTENSIBILITY OF THE LEVATOR HIATUS

Hypothesis / aims of study

Highly significant correlations exist between Female Pelvic Organ Prolapse (FPOP) and levator hiatal dimensions[1]. This relationship is not limited to hiatal dimensions on Valsalva- which may be explained a a passive phenomenon- but has also been confirmed for dimensions at rest. It is therefore probable that hiatal distensibility is an independent aetiological factor in the development of FPOP. However, to date there are no published data on how to define 'normal' and 'abnormal' hiatal dimensions. We therefore conducted a retrospective study with the aim of defining 'normality' for the parameter of 'hiatal area on Valsalva' through assessing its relationship with symptoms of prolapse.

Study design, materials and methods

We retrospectively analysed the data of 544 women seen in a tertiary urogynaecological unit for symptoms of pelvic floor and / or urinary tract dysfunction. A subset of this population had previously been studied for the prevalence of levator trauma and hiatal dimensions[1]. All patients had undergone a medical history and clinical examination for prolapse (ICS POPQ grading) and levator integrity and function (modified Oxford Grading) as well as 3D / 4D pelvic floor ultrasound using Medison SA 8000 and GE Kretz Voluson 730 expert systems. Ultrasound data acquisition was performed as described previously[2], with data acquired after bladder emptying, supine, at rest and on maximal Valsalva. Analysis of data was performed offline using the software 4D View (GE Kretz Ultrasound), weeks to months following clinical assessment, blinded against all clinical data. Hiatal dimensions were determined according to a previously published methodology[3], (see Figure 1). Receiver Operator Curves were used to analyse the relationship between hiatal dimensions and reported symptoms of prolapse (see Figure 2).

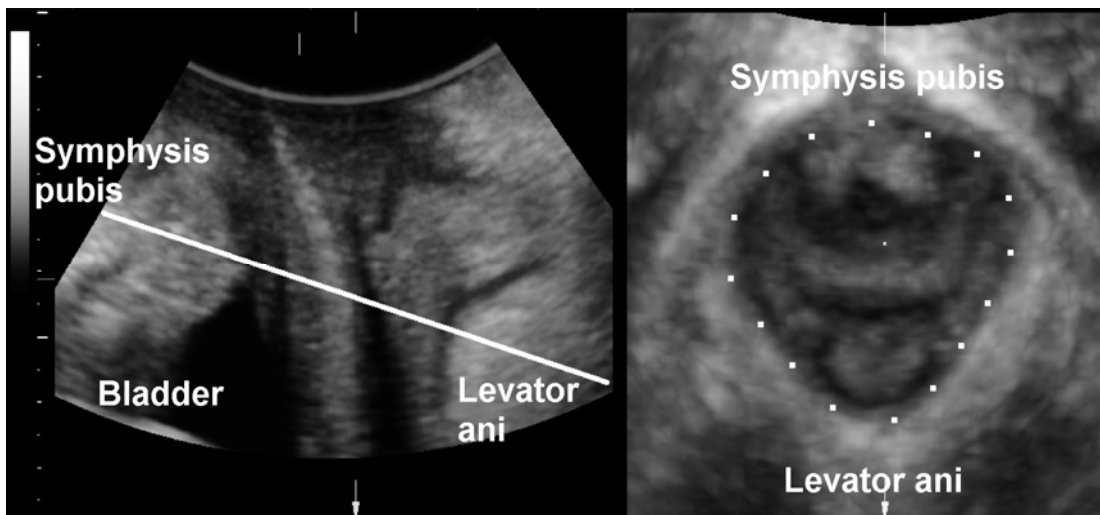


Figure 1: Identification of the plane of minimal hiatal dimensions on Valsalva. Translabial 4D ultrasound, midsagittal plane (left) and oblique axial plane (right). The dotted line illustrates hiatal area on Valsalva.

Results

Mean age of the study population was 53.2 (range 17 – 89). Median vaginal parity was 2 (range 0 – 8). On clinical history, information regarding prolapse symptoms was available for 538 women, with 171 (32%) complaining of such symptoms. Objective clinical examination revealed 185 Grade 1, 102 Grade 2 and 68 Grade 3 cystoceles. 61 women with Grade 1, 16 with Grade 2 and 8 with Grade 3 uterine prolapse and 187 Grade 1, 81 Grade 2 and 29 Grade 3 rectoceles. Data analysis revealed strong statistically relationship between reported symptoms of prolapse and all forms of prolapse (all $p < 0.001$). There was also a strong statistical relationship between reported prolapse symptoms and hiatal dimensions both at rest and on Valsalva (all $P < 0.001$). Receiver Operator Curve statistics confirmed this relationship, with an area under the curve of 0.65 (CI 0.60 – 0.70) for hiatal area at rest and 0.71 (CI 0.66 – 0.76) for hiatal area on Valsalva. Cut – offs of 25 and 30 cm² on Valsalva gave sensitivities of 0.55 and 0.34 and specificities of 0.77 and 0.86 respectively.

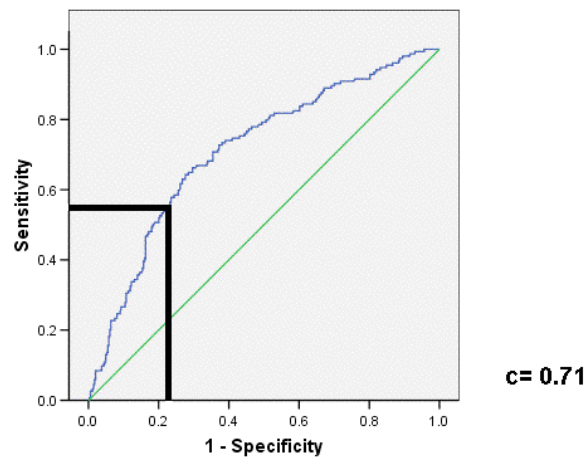


Figure 2: Receiver operator curve and the performance of a proposed cut-off of 25 cm² for the diagnosis of abnormal hiatal distensibility ('ballooning') on the basis of symptoms of prolapse.

Interpretation of results

Levator hiatal dimensions at rest and on Valsalva manoeuvre are strongly associated with symptoms of prolapse, as shown previously. On the basis of receiver operator curve characteristics and patient symptoms we propose a cut-off of 25 cm² for hiatal area on Valsalva, with measurements above this cut-off defined as 'ballooning' or abnormal distensibility of the hiatus. Our results are consistent with data obtained in young, nulliparous women in whom a purely mathematical definition of normality (mean + 2 SD) yielded a figure of 25.8cm²[3].

Concluding message

Hiatal dimensions measured using 3D translabial pelvic floor ultrasound are strongly associated with symptoms of prolapse, as shown previously. Hiatal distensibility is likely to be an independent aetiological factor for the development of female pelvic organ prolapse. Hence, normative data is needed. We suggest that a hiatal area of over 25cm² on Valsalva be defined as abnormal distensibility or 'ballooning' of the levator hiatus. On the basis of clinical experience it is proposed that 25-29.9 cm² be defined as 'mild', 30- 34.9 cm² as 'moderate', 35-39.9 cm² as 'marked' and 40 cm²+ as 'severe' ballooning.

References

1. Br J Obstet Gynaecol 2006. **113**(2): p. 225-30.
2. Ultrasound Obstet Gynecol, 2004. **23**(6): p. 615-625.
3. Ultrasound Obstet Gynecol, 2005. **25**: p. 580-585.

FUNDING: OZWAC Foundation, Penrith, Australia

HUMAN SUBJECTS: This study was approved by the Sydney West Area Health Service HREC and followed the Declaration of Helsinki Informed consent was not obtained from the patients.