

REPEATABILITY AND VALIDITY OF THE DIGITAL DETECTION OF LEVATOR TRAUMA

Hypothesis / aims of study

It has recently become clear that trauma to the levator ani muscle is a common consequence of vaginal childbirth[1]. While palpation for the diagnosis of such trauma has never been systematically assessed, it should be possible to detect major defects by digital examination. From previous data it appears that the correlation between palpation by a conventionally trained physiotherapist and ultrasound assessment may be very poor (κ 0.1)[2]. In comparison, the agreement between two trained examiners and magnetic resonance (MR) imaging of abnormal levator morphology has been shown to be acceptable[3], while agreement between palpation and MR for the detection of major defects seems limited[3]. In this study we tested for agreement between two trained examiners and between ultrasound and either of those two examiners.

Study design, materials and methods

110 women were seen in a tertiary urogynaecological unit. They were interviewed and underwent an examination using the ICS POP-Q staging system, assessment of the levator ani muscle by digital palpation as well as 3D/ 4D translabial ultrasound. The levator assessment was carried out independently by the two authors. Both examiners were blinded against ultrasound findings and against each other's clinical findings. The second observer had been trained for a total of over 100 cases (over a period of 3 months) before commencement of this study. Ultrasound volume data was retrospectively analysed using tomographic ultrasound (GE Kretz 4D View v 5.0), blinded against clinical results. Avulsion injury was diagnosed on palpation if there was a detachment of the pubovisceral muscle from its insertion on the inferior pubic ramus. On ultrasound we diagnosed an avulsion if there was evidence of a discontinuity between the pubovisceral muscle and the pelvic sidewall at the level of the levator hiatus and for at least 5 mm above this level.

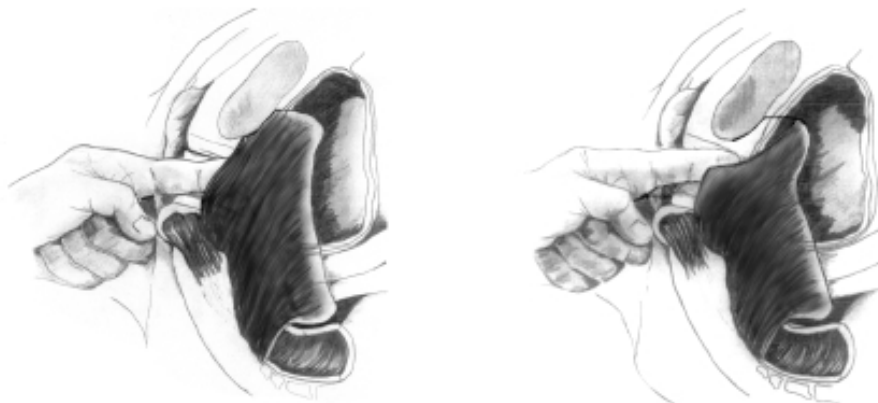


Figure: Palpation of the pubovisceral muscle for avulsion defects (normal situs on left, avulsion on right).

Results

Mean age was 55.5 (range 17- 85) years, median parity was 2 (range 0-8). Presenting complaints were stress incontinence (85/110) urge incontinence (82/110) and prolapse (46/110). Three patients could not be assessed due to vaginal atrophy or scarring, leaving 107 datasets representing 214 paired palpatory assessments of a right or left pubovisceral muscle. In 105 cases (210 single-sided assessments) this data could be correlated with tomographic ultrasound, as one volume datasets was missing, and another impossible to analyse due to artefact. Levator defects were found in 21/110 women (19%), with 9 bilateral defects.

On blinded assessment by palpation, there was agreement between assessors in 173/214 (81%), yielding a Cohen's kappa of 0.411, signifying moderate agreement. On analysing the first and last 50 cases separately, we found agreement in 78% for the first 50 and 84% for the last 50, indicating some degree of continuing teaching effect, despite the fact that the junior observer had previously undergone 3 months of training.

Agreement between the observers and an independent blinded review of tomographic ultrasound data was κ = 0.495 (observer 1) and κ = 0.382 (observer 2) for avulsion of the pubovisceral muscle. For observer 1 this equates to positive agreement (presence of defect) in 15/27 cases (56%) and negative agreement (absence of defect) in 170/ 183 cases (93%).

Interpretation of results

Even after substantial training, interobserver repeatability of digital palpation for the diagnosis of levator trauma remains moderate to poor (kappa 0.41). The overall agreement between observers was 81%, a figure that agrees with previously published data[3] in a study using magnetic resonance imaging for confirmation of findings. However, positive agreement between palpation and ultrasound may be higher than data reported for magnetic resonance imaging[3].

There clearly is a substantial learning curve for the palpatory detection of major levator trauma, and the latter seems less repeatable than identification of such defects by ultrasound (kappa= 0.83 on analysis of whole volumes and kappa= 0.61 for single slices) as shown previously.

Concluding message

It is feasible to diagnose avulsion of the pubovisceral muscle by digital vaginal examination. Palpation of such trauma correlates moderately well with an ultrasonic diagnosis of avulsion using 4D tomographic ultrasound. However, palpation seems less repeatable than ultrasound imaging, and it requires significant teaching.

References

1. Obstetrics & Gynecology, 2005. **106**(4): p. 707-12.
2. Neurourol Urodyn, 2006. **25**(5): p. 424-427.
3. Neurourol Urodyn, 2006. **25**(1): p. 50-4.

FUNDING: OZWAC Foundation, Penrith, Australia

HUMAN SUBJECTS: This study was approved by the Sydney West Area Health Service HREC and followed the Declaration of Helsinki Informed consent was not obtained from the patients.