

ANTIOXIDANT SUPPLEMENTATION DECREASES THE CELL DEATH IN THE PROSTATIC STROMAL TISSUE IN LONG-TERM CASTRATED RATS

Hypothesis / aims of study

On a histologic basis, evidence of abnormal prostatic enlargement can be found in 90% of the male population 85 years old or older. It is well established that the androgens are centrally involved in the regulation of the growth of the mammalian prostate gland, having the dual ability to stimulate the proliferation and to inhibit the death of glandular epithelial cells¹. Androgen deprivation by castration has been shown to induce rapid cell death in the ventral prostate via an apoptotic mechanism². Prostatic cells may respond to oxidative stress insult by undergoing apoptosis. Our major objective herein was to compare the effects of castration on cell death in the adult rat prostate. Furthermore it was also to evaluate the benefic action of alpha tocopherol supplementation in avoiding the apoptosis post-orchietomy.

Study design, materials and methods

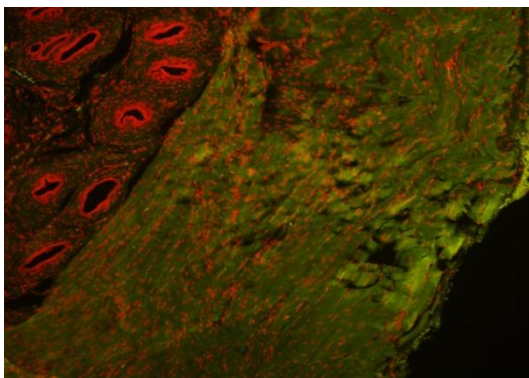
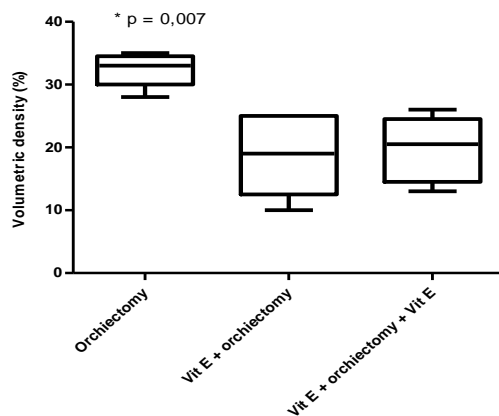
The project was approved by the University Ethical Committee.

Fifteen male rats of wistar breed weighing 250-300g were used, divided into three groups: **group I** –subjected to bilateral orchietomy and sacrificed eight weeks after the procedure; **group II** – subjected to bilateral orchietomy with alpha-tocopherol supplementation for four weeks preceding the procedure; and **group III** – subjected to bilateral orchietomy with alpha-tocopherol supplementation for four weeks preceding the procedure and for eight weeks afterwards. At the end of the experiment, the prostatectomy was performed. The presence of oxidative stress was determined by means of assaying the blood level of 8-isprostane and occurrences of apoptosis were evaluated by means of identifying active caspase-3 through immunohistochemical analysis. Kruskal-Wallis test was used for the statistical analysis.

Results

The apoptotic indices of caspases in the different groups are described in figure 1 and illustrated in figure 2 (a-c). The statistic analysis of active caspase-3 showed that in the long-term orchietomized group the detection was higher than in groups were the alpha-tocopherol was replaced ($p=0,007$). Analysis of 8-isoprostane levels showed high concentrations of oxygen-reactive species in group I, in the other groups ($p<0,05$). Groups II and III presented active caspase-3 levels that were lower than in group I ($p<0,05$).

Figure 1. The apoptotic indices of caspases (%) in the different groups.



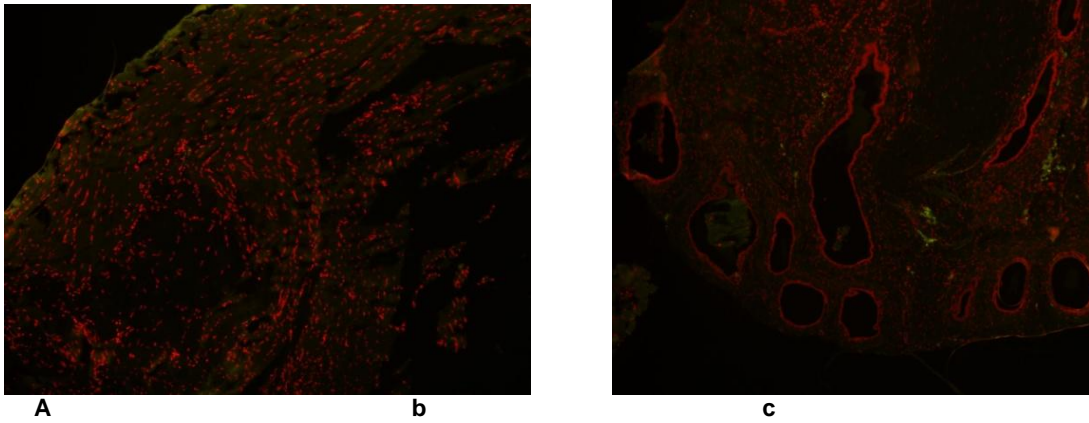


Figura 2: Microscopic fluorescence immunohistochemistry for the detection of active caspase-3. Increase 10x, groups I(a), II(b) and III(c). The positive reaction is visualized in green. Nuclei are observed in red.

Interpretation of results

A more intense concentration of 8-isoprostane, which may be indicated of oxidative stress, occurred in the prostate of orchiectomized rats. In those same animals the apoptotic process was also higher than in the other groups. The supplementation of alpha tocopherol was able to avoid the amount of cells death induced by androgen deprivation and oxidative stress; corroborating the hypothesis that alpha-tocopherol has a protective effect in relation to apoptosis induced by oxidative stress.

Concluding message

Our exploratory analyses serve as a demonstration of a method to study the aging process and its influence on oxidative stress prostatic tissue and cells death. Based on our results we can suggest the alpha tocopherol supplementation can decrease the apoptotic process as well as the oxidative stress levels induced by androgen deprivation on the prostate gland.

References

- ¹ Endocrinology (1995) 136;4368-4376.
- ² Reproduction (2004) 127;359-366.

Specify source of funding or grant	NONE
Is this a clinical trial?	No
What were the subjects in the study?	ANIMAL
Were guidelines for care and use of laboratory animals followed or ethical committee approval obtained?	Yes
Name of ethics committee	ETHICAL COMMITTEE OF FEDERAL UNIVERSITY OF SAO PAULO