

**MAGNETIC RESONANCE IMAGING OF ABDOMINAL VERSUS VAGINAL PROLAPSE SURGERY WITH MESH**Hypothesis / aims of study

Vaginal monofilament polypropylene mesh (MPM) repair versus abdominal sacrocolpopexy (ASCP) repairs of pelvic organ prolapse (POP) will result in different anatomic outcomes, demonstrable on magnetic resonance imaging (MRI). This hypothesis is based on prior MRI studies comparing ASCP with transvaginal sacrospinous ligament fixation, which showed that the normal vaginal axis was best restored by ASCP (1,2).

The aim of the study is to compare two surgical approaches in patients with symptomatic prolapse of the vaginal apex, with normal controls, by analyzing MRI measured pelvic landmark relationships and quality of life (QOL) measures, before and after surgery.

Study design, materials and methods

Prospective pilot study of a multicenter surgical trial (n=16). Normal controls consisted of 6 nulliparous volunteers without prior pelvic surgery, with a uterus, and prolapse < stage 2. The study group included 10 parous (3.0±1.0) women with a uterus and prolapse of the vaginal apex ≥ stage 2, requesting definitive surgical correction. Five patients underwent ASCP (Group A) (using MPM from the cervical stump to the sacral promontory), and 5 patients underwent vaginal MPM kit repair (total ProLift, Gynecare/Ethicon, Sommerville, NJ, USA) (group B) at the discretion of the operating surgeon. Subtotal hysterectomy was performed in all five patients in group A. None of the patients in group B underwent hysterectomy. All study patients underwent pre-op and 3 months post operative POPQ exam, dynamic MRI at rest and during maximal valsalva, validated health status, quality of life (QOL) and sexual function questionnaires (SF-36, PFIQ-7, PISQ-12, PFDI-20).

	Control group (n = 6)	Study group A Pre-operative (n = 5)	Study group B Pre-operative (n = 5)	Study group A Post-operative (n = 5)	Study group B Post-operative (n = 5)
POPq-C	-6.3 ± 1.2	0.4 ± 0.9*	-0.3 ± 1.5*	-7.2 ± 1.6 <sup>^</sup>	-5.8 ± 0.4 <sup>#</sup>
QOL questionnaires:					
SF-36 (Daily activities)	26.5 ± 7.1	22.2 ± 4.4	24.6 ± 3.9	28.6 ± 1.7 <sup>^</sup>	27.2 ± 2.2
PFIQ-7 (Pelvis/vagina)	0 ± 0	2.8 ± 2.9	5.8 ± 5.4*	1.8 ± 2.7	0 ± 0 <sup>#</sup>
PFIQ-7 (Bladder/urine)	2.0 ± 3.3	4.6 ± 4.6	8.0 ± 3.0*	2.0 ± 2.8	0.8 ± 1.8 <sup>#</sup>
PFDI-20	4.7 ± 9.2	13.8 ± 9.9	22.2 ± 4.3*	4.6 ± 4.4	8.2 ± 8.3 <sup>#</sup>
MRI:					
Bladder neck to PCL at rest (cm)	-2.0 ± 0.6	0.2 ± 1.4*	-1.0 ± 1.2	-1.1 ± 0.8	-0.8 ± 1.1
e angle at rest (°)	135.2 ± 10.9	161.4 ± 37.1	164.0 ± 27.1*	154.4 ± 16.9 <sup>‡</sup>	139.0 ± 17.6
h angle at rest (°)	14.3 ± 7.9	26.2 ± 10.4*	26.6 ± 14.7	16.0 ± 13.3	16.2 ± 7.3
g angle at rest (°)	-9.8 ± 14.1	7.0 ± 8.8*	12.6 ± 11.2*	17.8 ± 13.6 <sup>‡</sup>	13.6 ± 10.2 <sup>‡</sup>

POPq-C - Pelvic organ prolapse quantification point C

SF-36 (Daily activities) - total score range 10-30

PFIQ-7 - Pelvic Floor Impact Questionnaire 7 (total score range 0-21)

PFDI-20 - Pelvic Floor Distress Inventory 20 (total score range 0-60)

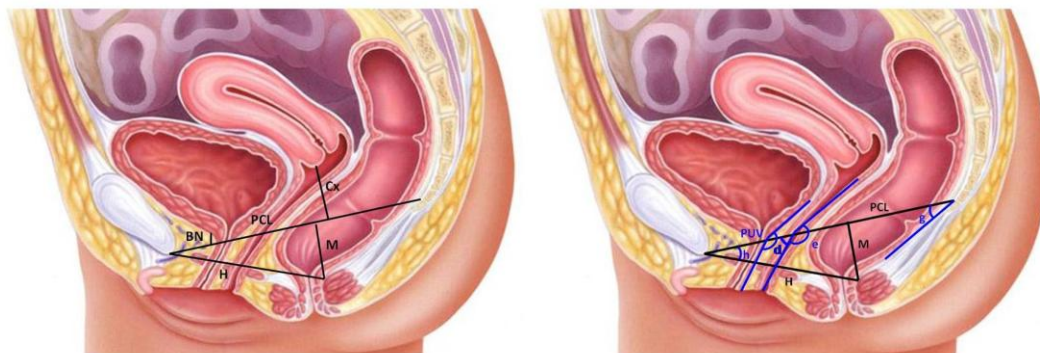
\*comparison between the study group pre-operatively and the control group (p<0.05)

<sup>^</sup>comparison between the study group A pre-operatively and post-operatively (p<0.05)

<sup>#</sup>comparison between the study group B pre-operatively and post-operatively (p<0.05)

<sup>‡</sup> comparison between the study group post-operatively and the control group (p<0.05)

Comparison of support through analysis of MRI, pelvic angles, and distances (Figure 1) was performed by an experienced radiologist. Data was analyzed by SPSS statistical software using Mann-Whitney Rank Sum test and chi-square test.



**PCL (Pubococcygeal Line):** line from the inferior border of the pubic symphysis to the last joint of the coccyx  
**H (H-line):** line from the inferior border of the symphysis pubis to the posterior wall of the rectum at the level of the anorectal junction  
**M (M-line):** perpendicular line from the PCL to most posterior aspect of the H-line  
**BN (Bladder neck line):** perpendicular line from the most inferior border of the bladder to the PCL  
**Cx (Cervix line):** perpendicular line between most inferior border of uterine cervix to PCL  
**d angle:** Angle between lower vagina and PCL  
**e angle:** Angle between lower and upper vagina  
**g angle:** Angle between levator plate and PCL  
**h angle:** Angle between H-line and PCL  
**PUA (Posterior urethrovesical angle):** Angle between posterior border of the bladder and the urethra

## Results

Study group patients were significantly older than control ( $59.7 \pm 9.3$  versus  $27.4 \pm 3.5$  years,  $p=0.003$ ). The main findings in comparison between the control group and the study group (preoperative and postoperative) are summarized in table 1. Although the patients in the study group B were significantly older than study group A patients ( $67.2 \pm 8.4$  years versus  $53.6 \pm 8.3$  years,  $p=0.03$ ), there were no significant differences in terms parity, menopausal status and BMI. There was no difference in general health and quality of life scores between the groups postoperatively. There was no difference in any of the above MRI landmarks postoperatively.

## Interpretation of results

This pilot study shows that both surgical approaches yielded similar anatomic and QOL results postoperatively. Changes in the g angle, even post-operatively, may reflect levator atrophy. Longer follow-up with larger numbers seems warranted.

## Concluding message

ASCP compared to Prolift for vaginal apical support are similar at three months as indicated by POPQ and MRI analysis and QOL measures. Both treatment returned POPQc and QOL measures to values comparable to nulliparous controls by 3 months.

## References

1. Sze EH, Meranus J, Kohli N, Miklos JR, Karram MM. Vaginal configuration on MRI after abdominal sacrocolpopexy and sacrospinous ligament suspension. *Int Urogynecol J Pelvic Floor Dysfunct* 2001; 12(6):375-9.

2. Rane A, Lim YN, Withey G, Muller R. Magnetic resonance imaging findings following three different vaginal vault prolapse repair procedures: a randomised study. Aust N Z J Obstet Gynaecol 2004 Apr; 44(2):135-9.

<b><i>Specify source of funding or grant</i></b>	<b>No Grants</b>
<b><i>Is this a clinical trial?</i></b>	<b>Yes</b>
<b><i>Is this study registered in a public clinical trials registry?</i></b>	<b>No</b>
<b><i>What were the subjects in the study?</i></b>	<b>HUMAN</b>
<b><i>Was this study approved by an ethics committee?</i></b>	<b>Yes</b>
<b><i>Specify Name of Ethics Committee</i></b>	<b>Mount Sinai School of Medicine, NY, NY, USA GCO #06-1443</b>
<b><i>Was the Declaration of Helsinki followed?</i></b>	<b>Yes</b>
<b><i>Was informed consent obtained from the patients?</i></b>	<b>Yes</b>