

ANATOMICAL STUDY OF TVT-S IN THE U-POSITION

Hypothesis / aims of study

TVT-S is the third generation of tension-free vaginal tapes. There are two possible insertion methods: the H-position and the U-position. It was claimed that this tape, using less foreign material, would achieve same efficacy and a reduction of the complication rate in comparison to the previous methods [1]. The aim of the study was to evaluate the fixation site of the TVT-S tape in the U-position and describe possible complications. Until present day there is no study about anatomy of the TVT-S in the U-position. We hypothesize that fixation site will be crucial for long-term efficacy of the method.

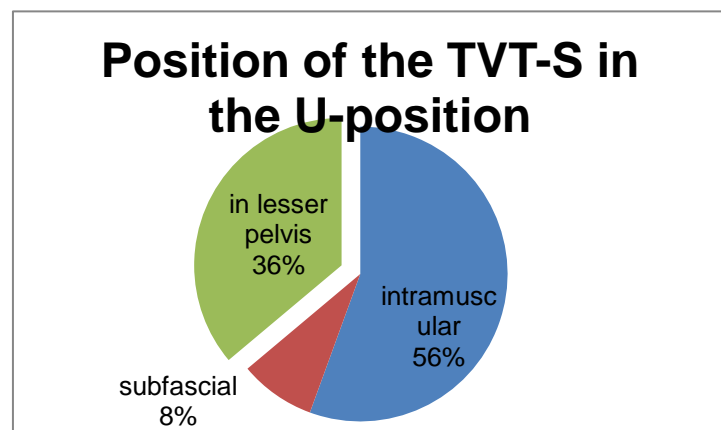
Study design, materials and methods

We used a total of eighteen female cadavers - thirteen formalin-embalmed and five fresh frozen. TVT-S was placed in the U-position as recommended by the manufacturer in the instructions. The only way this placement deviated from the recommended procedure was in the position of the legs of the formalin-embalmed bodies, due to the rigidity of the limbs. It was necessary for the flexion in the hip joint to be 30° instead of 90°. This was also the reason for the inclusion of fresh frozen cadavers, since the position of legs might be important for proper insertion; the previous methods - especially trans-obturator tapes - are known to depend on it. After the insertion abdominal dissection of the lesser pelvis was performed, distances to the obturator nerve were measured as a safety parameter, and the site of fixation was examined. For statistical analysis we used 5% level of significance alpha, and the data were processed by the system R. To compare the difference between the group of fresh frozen and formalin-embalmed bodies we used the *t* test and Wilcoxon-paired test. We made a rough estimate of standard deviation SD from given data as 1.0 cm. At a 5% level of significance and with the power of the test 80%, the numbers of fresh frozen bodies and embalmed female bodies needed to detect the mean difference delta of 0.5 cm, we would need 42 fresh frozen bodies and 127 embalmed female bodies. In our study, we would be able to detect a mean difference of approximately 1.5 cm.

Results

In total we examined 36 trajectories and fixation sites of TVT-S. The mean distance from the obturator nerve was 2.66 cm (SD 0.95 cm) on the left and 2.71 cm (SD 1.20 cm) on the right. None of the tests for differences in the distance to the obturator nerve and the fixation site between the group of fresh frozen bodies and formalin-embalmed bodies was significant.

In 36.1% of the cases the inserter penetrated into the lesser pelvis with the following results (Tab. 1). Once the inserter was inside the urinary bladder; in twelve cases the inserter was prevesical, i.e. between the urinary bladder and the fascia of obturator internus muscle. In one case the inserter was in close contact with the obturator nerve – less than 1 mm (Fig. 1).



Tab. 1

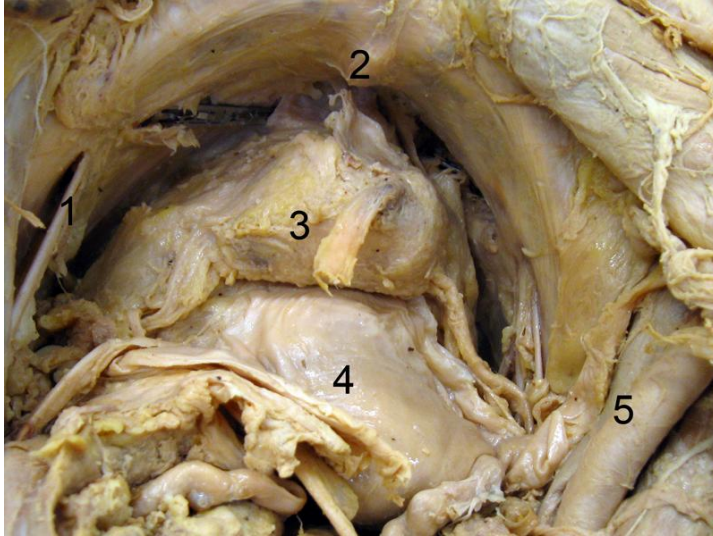


Fig. 1
1 left obturator nerve, 2 pubic symphysis, 3 urinary bladder, 4 uterus, 5 right external iliac artery and vein

Interpretation of results

TVT-S appears to be less depending on position of the legs during the procedure. Nevertheless, frequency of the perforation of the fascia of obturator internus muscle is alarming and is quite similar to long-term efficacy published by clinicians. In case of inserting the tape into lesser pelvis possible complications, as perforation of the urinary bladder or

haemorrhage, can occur. In the case of perforation of the fascia of obturator internus muscle, haemorrhage will be less likely to stop by self-compression.

Concluding message

TVT-S has a high risk of placement into the small pelvis with risk of injury to vessels, urinary bladder and variable anatomical structures. Excessive movement with the inserter might cause severe complications. Position of the legs seems to be less important for TVT-S than for previous methods. TVT-S in the U-position endangers the obturator nerve.

References

1. Neuman M (2007) Training TVT Secur: the first 150 teaching operations. Int Urogynecol J Pelvic Floor Dysfunct 18 Suppl 1:S27

<i>Specify source of funding or grant</i>	This study was supported by the Internal Grant Agency of The Ministry of Health of the Czech Republic, grant NS 10586-3/2009, GIGH-0651-00-3-223 and by project of The Ministry of Education, Youth and Sports VZ 0021620806.
<i>Is this a clinical trial?</i>	No
<i>What were the subjects in the study?</i>	NONE