

TAPE POSITION IN PATIENTS WITH RECURRENT URINARY INCONTINENCE AFTER FAILED SUBURETHRAL SLINGS

Hypothesis / aims of study

Established risk factors for suburethral sling failure include: age, intrinsic sphincter deficiency, concomitant or previous surgery and surgeon's experience. Less attention has been paid to the tape position under the urethra. It has been shown that when a TVT lays between the 50th and 80th percentile of the urethral length (measured from the bladder neck), the cure rate exceeds 90%, whereas location outside this zone is associated with failure in more than one-third of patients (1). In case of a TVT-O worse treatment results are achieved with position of a tape under the proximal half of the urethra (2). On the contrary, some studies showed that there is no association between tape position and cure rate of suburethral slings (3).

Aim of our study was to evaluate the tape position under the urethra in patients with recurrent urinary incontinence after sling procedures using 3-D transvaginal ultrasound.

Study design, materials and methods

The study group comprised 28 patients referred or readmitted to our department due to failure of treatment with suburethral sling procedures. The age of the subjects ranged from 47 to 80 years (mean 61.6 years) and BMI from 20.4 to 46.7 (mean 28.9). All but three women complained of stress urinary incontinence. In two cases mixed urinary incontinence with a predominant stress component was diagnosed. In one case de novo urgency concomitant with permanent urine leakage developed shortly after the surgery. Twenty-four women were initially treated with transobturator sling and six with supraubic procedure. Position of the tape was evaluated with transvaginal ultrasound using a linear transducer (type 8848, B-K Medical, Denmark).

Results

In 20 (71.4%) of women a tape was found under the proximal half of the urethra. Six patients (21.4%) had a tape located between the 50th and 80th percentile of the urethral length (measured from the bladder neck) and 2 (7.1%) over the 80th percentile.

Interpretation of results

Only approximately 20% of women from our series had tapes located between the 50th and 80th percentile of the urethra, which may be regarded as an optimal position in terms of tape functionality. In most of the subjects tapes were positioned outside this zone, predominantly under the proximal half of the urethra. It is uncertain whether wrong tape position may result from an inadequate surgical technique or slippage of a tape in the postoperative period.

Concluding message

Tape position under the urethra should be taken into account as an important risk factor for failure of suburethral slings in women with stress urinary incontinence.

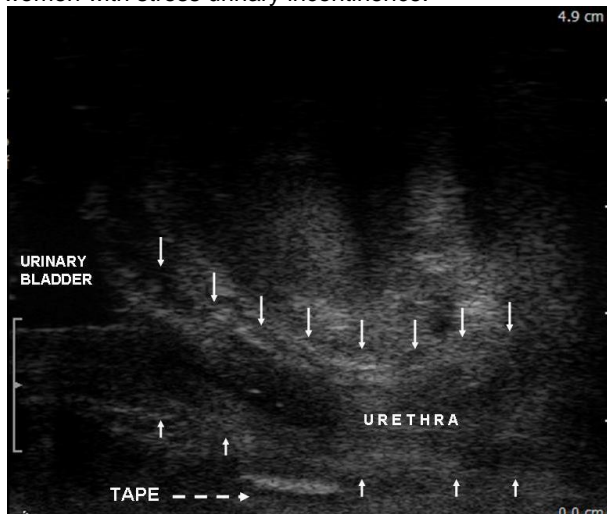


Figure 1. Transobturator tape located under the midurethral.

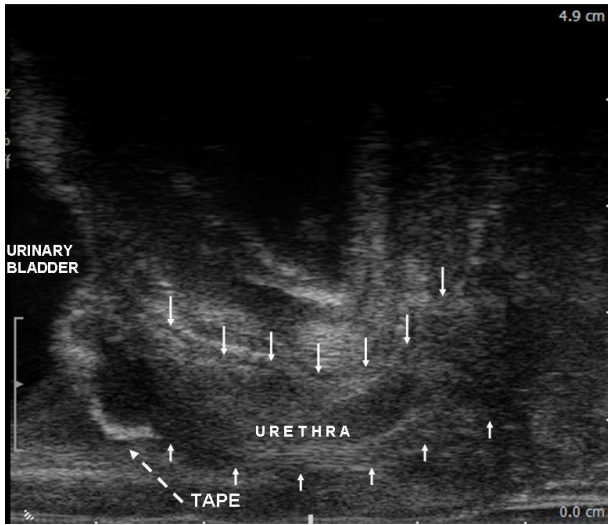


Figure 2 Transobturator tape located close to the bladder neck.

References

1. Kociszewski J, Rautenberg O, Perucchini D et al. Tape Functionality: Sonographic tape characteristics and outcome after TVT incontinence surgery. *Neurourol Urodynam* 2008;27:485–490
2. Yang JM, Yang SH, Huang WC. Correlation of morphological alterations and functional impairment of the tension-free vaginal tape obturator procedure. *J Urol* 2009;181:211–218.
3. Ng CCM, Lee C, Han WH et al. Use of three-dimensional ultrasound scan to assess the clinical importance of midurethral placement of the tension-free vaginal tape (TVT) for treatment of incontinence. *Int Urogynecol J Pelvic Floor Dysfunct* 2005;16:220–225.

Specify source of funding or grant	Medical University of Lublin grant no PW410
Is this a clinical trial?	No
What were the subjects in the study?	HUMAN
Was this study approved by an ethics committee?	Yes
Specify Name of Ethics Committee	Medical University of Lublin Ethics Committee
Was the Declaration of Helsinki followed?	Yes
Was informed consent obtained from the patients?	Yes