

# NEW Continent Augmentation cystoplasty with Umbilical Cateterisable Stoma

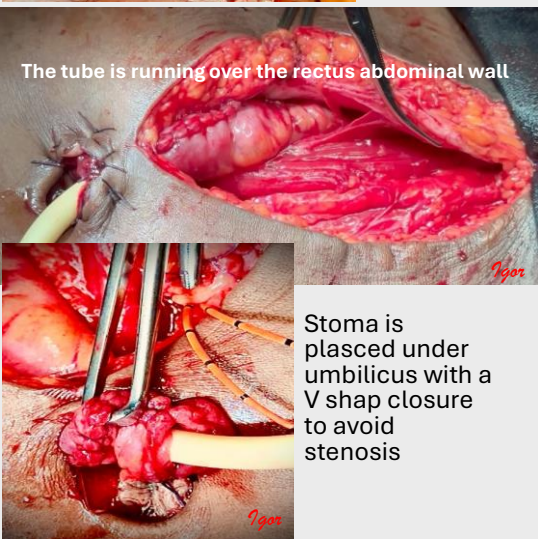
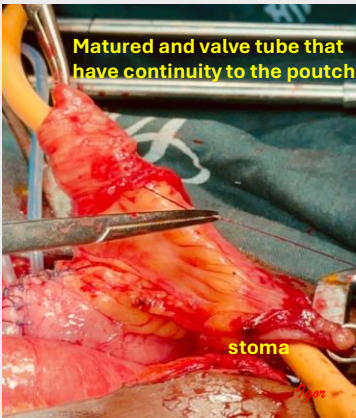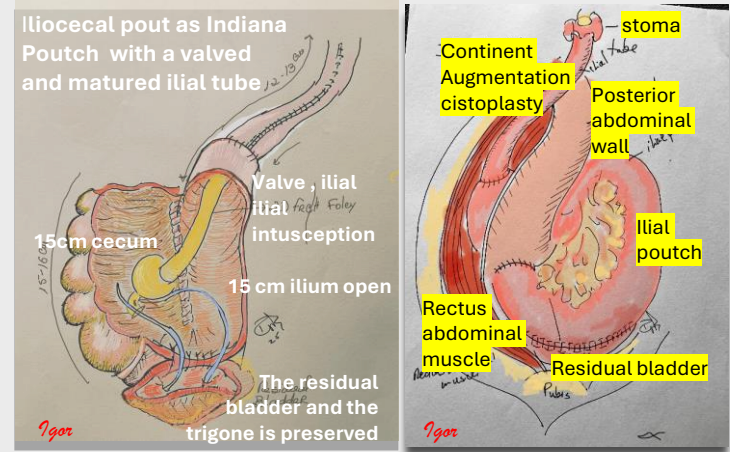
1. VAZ, IGOR,
- FOCUS FISTULA ASSOCIATION  
ISOFS President
  - igor.vaz@focusfistula.org.mz

**Obstetric fistula with total destruction of the bladder neck and urethra** remains a devastating condition in many parts of the world, particularly sub-Saharan Africa. Diversion will be the best solution, but which diversion remain unclear

**a new continent urinary diversion technique** using a J-shaped ileal or ileocecal neobladder Studer and Indiana pouch modification with a Matured and valved cateterisable umbilical stoma providing a good continence, cosmetic excellent result.

“no one will be left behind”

info@focusfistula.org.mz  
www.focusfistula.org.mz  
www.facebook.com/focusfistula



## TAKE HOME MESSAGES

**DIVERSIONS to the sigmoid should be avoided due to the complications**

**ICS - abdominal stomas of the ICS not well accepted cosmetically and for absence of appliances**

**CONTINENT CATHETERIZABLE BLADDERS have shown acceptable levels of complications and are extremely well accepted in Africa, but Mitrofanoff have a higher n°s of stenotic complications**

**GOOD CONTINENCE WAS ACHIEVED IN THE LAST 19 SUBMITTED TO THE DIVERSION**

Tip of surgery	Nº of cases	continence	Renal function	Heandling difficulties	Cosmetic	Folowing the advises
Matured and valved ilial tube in augmentation cystoplasty	12	Good	No modification	no	good	good
Matured and n valved ilial tube neo cystoplasty	3	good	No modification 1 case worst	no	good	good
Matured and Valved ilial tube in a neo bladder from bowel	4	good	No Modification	1 cases strictures	good	good
Total	19	Good				good