

Sakakibara R<sup>1</sup>, Doi H<sup>2</sup>, Tateno F<sup>1</sup>, Kishi M<sup>1</sup>, Tsuyusaki Y<sup>1</sup>, Tateno H<sup>1</sup>, Aiba Y<sup>1</sup>, Yamamoto T<sup>3</sup>, Uchiyama T<sup>4</sup>, Shibata C<sup>4</sup>, Yamanishi T<sup>4</sup>

1. Neurology, Internal Medicine, Sakura Medical Center, Toho University, 2. Pharmaceutical Unit, Sakura Medical Center, Toho University, 3. Neurology, Chiba University, 4. Continence Center, Dokkyo Medical College

## LEVODOPA DOES NOT WORSEN GASTROPARESIS AND SLOW TRANSIT CONSTIPATION IN PARKINSON'S DISEASE

### Hypothesis / aims of study

Gut disorder significantly affects quality of life of patients with Parkinson's disease (PD), since it leads to gastroparesis (bloating, nausea, vomiting), interfering with levodopa absorption (motor delayed-on, malignant syndrome), constipation, and in most advanced cases, intestinal pseudo-obstruction (ileus) and stercoral (stool) ulcer. Levodopa is a mainstay in the treatment of motor disorder in PD. In contrast, little is known about levodopa's effect on the gut function in PD, despite a study that dopamine worsens gut function in a non-PD cohort. The aim of this study is to present the results of our gastric emptying (GE) using <sup>13</sup>C-sodium acetate expiration breath and colonic transit time (CTT) analyses before and after administration of levodopa/carbidopa in patients with PD.

### Study design, materials and methods

1) Fifteen untreated patients with PD; 5 men and 10 women; mean age, 69 years; disease duration, 1.4 years, were enrolled in the breath study. All patients underwent a gastrointestinal questionnaire and the breath test before and after 15 months, 193.0 ± 25.8 mg/day administration of levodopa.

2) Nineteen untreated patients with PD; 10 men and 9 women; mean age, 66 years; disease duration, 2.2 years, were enrolled in the CTT study. All patients underwent a questionnaire, the CTT test before and after 3 months, 200 mg/day administration of levodopa. Statistical analysis was performed by Student's *t*-test.

### Results

Levodopa was well tolerated by all patients and none had abdominal pain or other adverse effects.

1) Tmax (<sup>13</sup>C) in our untreated PD was prolonged (54.3 min) as compared with normative data (43.9 ± 10.3 min, n=63). Levodopa did not change mean Tmax (<sup>13</sup>C) significantly (54.3 ± 15.0 min to 53.3 ± 17.5 min) [figure 1]. Since Tmax (<sup>13</sup>C) in PD patients before levodopa was diverse, according to the normative data (43.9 ± 10.3 min, n=63), we divided them into two groups; e.g., delayed group (Tmax (<sup>13</sup>C) ≥ 60 min) and normal group (Tmax (<sup>13</sup>C) < 60 min). As a result, levodopa tended to shorten Tmax (<sup>13</sup>C) in delayed group (not significant). This acceleration was not noted in normal group.

2) Total CTT in our untreated PD was prolonged (49.3 hours) as compared with normative data (39 hours, n=10) [figure 2]. Levodopa did not significantly change CTT of the total colon (49.3 to 56.7 hours) or CTT of the right, left, or rectosigmoid segment either before or after treatment. [table 1]. (Along with this, videomanometry showed lessened first sensation volume (178.6 ml to 121.3 ml) and lessened post-defecation residuals (142.2 ml to 53.9 ml)).

### Interpretation of results

We did not find a change in GE and CTT after levodopa, suggesting that levodopa does not worsen GE and CTT in PD. Previously, dopamine lessened gastroduodenal motility in critically ill patients. <sup>1</sup> Conversely, dopamine receptor blocker itopride facilitates gastric motility <sup>2</sup>. Both drugs do not easily penetrate the blood-brain barrier [BBB]. In contrast, levodopa /carbidopa (peripheral dopa decarboxylase inhibitor) formula does not act on peripheral dopamine receptors, maximizing BBB penetration, bringing about different gut effect than dopamine/ itopride. A recent study favoured this assumption that deep brain stimulation shortened GE in PD.<sup>3</sup>

### Concluding message

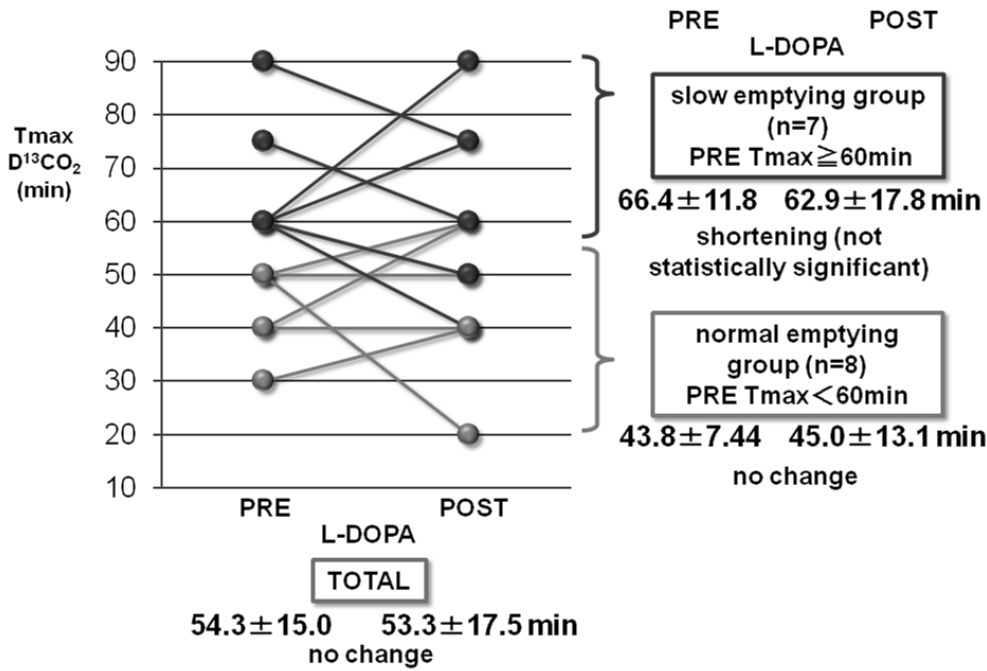
Although this is a pilot study, we did not find a change in GE and CTT after levodopa, suggesting that levodopa does not worsen GE and CTT in untreated PD patients.

	total colon (hours)	right (hours)	left (hours)	rectosigmoid (hours)
before	49.3	10.0	12.5	26.6
after	56.7	9.7	15.4	31.6
paired t-test	NS	NS	NS	NS

**Table 1 Effect of levodopa on colonic transit in Parkinson's disease patients.**

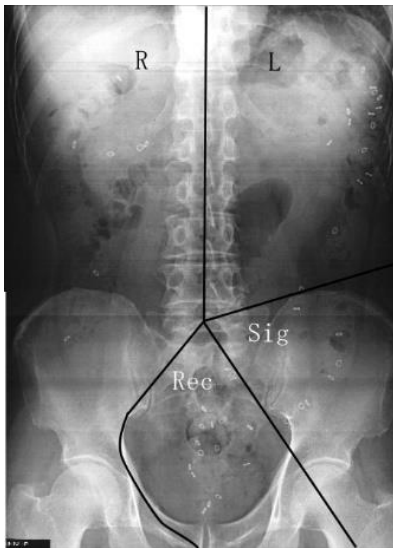
Levodopa did not significantly change colonic transit time (CTT) of the total colon (49.3 to 56.7 hours) or CTT of the right, left, or rectosigmoid segment before and after the treatment.

NS: not significant.



**Figure 1 Effect of levodopa on gastric emptying in Parkinson's disease patients.**

Levodopa did not change mean Tmax (<sup>13</sup>C) significantly (54.3 ± 15.0 min to 53.3 ± 17.5 min). Since Tmax (<sup>13</sup>C) in PD patients before levodopa was diverse, according to the normative data (43.9 ± 10.3 min, n=63), we divided them into two groups; e.g., delayed group (Tmax (<sup>13</sup>C) ≥ 60 min) and normal group (Tmax (<sup>13</sup>C) < 60 min). As a result, levodopa tended to shorten Tmax (<sup>13</sup>C) in delayed group (not significant). This acceleration was not noted in normal group.



**Figure 1 Colonic transit study.**

References

1. Dive A, Foret F, Jamart J, et al. Effect of dopamine on gastrointestinal motility during critical illness. *Intensive Care Med* 2000; 26: 901-907.
2. Sakakibara R, Kishi M, Ogawa E, et al. Bladder, bowel, and sexual dysfunction in Parkinson's disease. *Parkinsons Dis*. 2011:924605. Epub 2011 Sep 12.
3. Arai E, Arai M, Uchiyama T, Higuchi Y, Aoyagi K, Yamanaka Y, Yamamoto T, Nagano O, Shiina A, Maruoka D, Matsumura T, Nakagawa T, Katsuno T, Imazeki F, Saeki N, Kuwabara S, Yokosuka O. Subthalamic deep brain stimulation can improve gastric emptying in Parkinson's disease. *Brain*. 2012 May;135(Pt 5):1478-85.

Disclosures

**Funding:** We have no sponsors. **Clinical Trial:** No **Subjects:** HUMAN **Ethics Committee:** Ethic Committee in Sakura Medical Center, Toho University **Helsinki:** Yes **Informed Consent:** Yes