

## UNILATERAL CORONAL DIAMETERS OF THE LEVATOR HIATUS: BASELINE DATA FOR THE AUTOMATED DETECTION OF AVULSION OF THE PUBORECTALIS MUSCLE

### Hypothesis / aims of study:

Levator avulsion injury is associated with pelvic organ prolapse (1) and very likely a major etiological factor in the pathogenesis of this condition. Diagnosis of avulsion is undertaken using magnetic resonance imaging or translabial 3D/ 4D pelvic floor ultrasound (2). Since either requires substantial teaching, automated detection would be of advantage, and modern volume ultrasound provides suitable raw data. The high contrast between hyperechogenic muscle and hypoechoic vaginal tissues should in principle allow detection of the outline of the levator hiatus by software algorithms. In order to allow identification of abnormalities, unilateral biometric measures predictive of levator trauma need to be defined.

### Study design, materials and methods:

The data of patients seen in a tertiary urogynaecology clinic between May 2005 and November 2008 were reviewed retrospectively. A history was obtained using a structured interview. Patients underwent a clinical examination, using the ICS POP-Q system. Imaging was undertaken with GE Voluson 730 Expert and Voluson I ultrasound systems with 8-4 MHz volume transducers (acquisition angle 85°). The examination was carried out after voiding with patients in modified lithotomy with hips and knees flexed, resorting to the standing position in those patients who were unable to perform a Valsalva without levator activation. Patients were also asked to perform a maximal pelvic floor muscle contraction (PFMC). Stored ultrasound volume datasets were analysed at a later date using proprietary software. The maximum unilateral coronal diameter of the levator hiatus was measured in the plane of minimal hiatal dimensions in a volume dataset obtained at maximal PFMC, blinded against clinical data. A central line was drawn through the coronal plane (representing the sagittal midline), and the distance between this line and the widest point of the levator hiatus was measured on both sides, as shown in Figure 1a. In women without avulsion, hiatal symmetry allowed the use of 1/2 of the total coronal diameter, avoiding the need for two separate measurements.

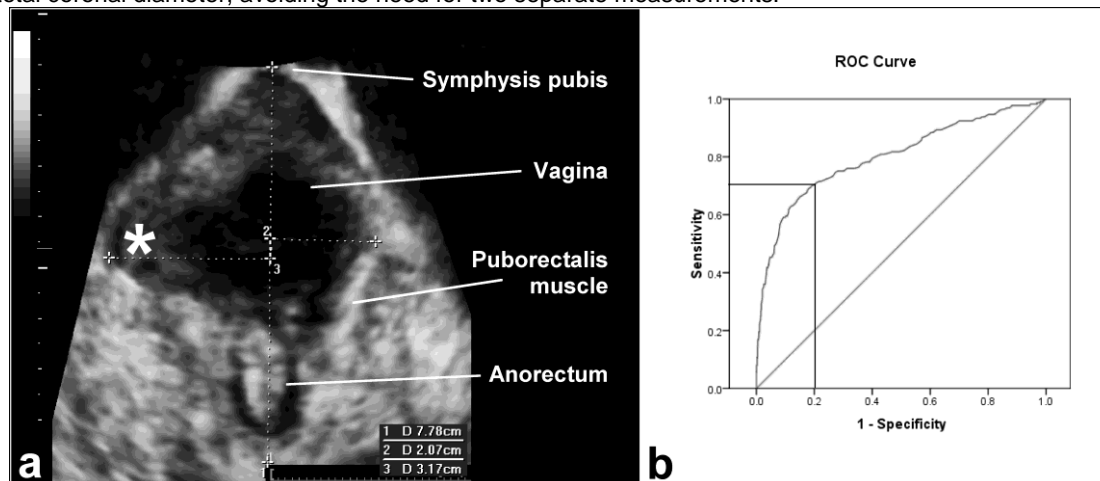


Figure 1a: Axial plane view of the levator hiatus on maximal PFMC in a patient with right-sided avulsion (indicated by \*). Dotted lines represent the midsagittal plane (vertical line) and the two unilateral coronal diameters; b: ROC curve (AUC 0.801, CI 0.765-0.837) for the use of this measurement as a predictor of the diagnosis of levator avulsion injury. The vertical and horizontal lines signify the cut-off of 2.3 cm.

All measurements were carried out by the first author. A test re-test series of 25 patients showed an intra-class correlation for individual measurements of 0.819 (95% confidence interval, 0.701 – 0.893). The main outcome parameter was levator ani avulsion injury. The explanatory parameter was unilateral maximum coronal diameter at the time of pelvic floor muscle contraction and, if unavailable, at rest. Receiver operator characteristics (ROC) curves were plotted to determine an appropriate cut-off for the diagnosis of avulsion injury.

### Results:

A total of 787 patients were identified, and 761 volume datasets (96.7%) were available for post-processing. Twenty-six volumes were unavailable due to failure to save (n=20), clerical error (n=1) and poor imaging quality (n=5). These patients were excluded from further analysis. Of 761, 16 (2.1%) had been unable to perform a pelvic floor muscle contraction, and volumes at rest were used instead. Demographic data are shown in Table 1. We obtained 1522 unilateral measurements (2 sides for 761 patients) which were tested against the diagnosis of avulsion as reached by tomographic pelvic floor ultrasound. Avulsion was associated with a markedly increased unilateral coronal diameter ( $2.57 \pm 0.5$  vs  $2.1 \pm 0.3$ ,  $P < 0.0001$ ). Figure 1b shows this association in the form of a receiver operating characteristics curve, demonstrating an area under the curve of 0.801 (95% confidence interval 0.765 – 0.837). An optimum cut-off for the diagnosis of avulsion on the basis of one single unilateral coronal diameter measurement was 2.3 cm, yielding a sensitivity of 71% and a specificity of 79%.

| Parameter                        |             |
|----------------------------------|-------------|
| Age (mean / SD)                  | 54.6 ± 14.4 |
| Presenting symptoms [number (%)] |             |
| - Stress incontinence            | 538 (70.7%) |
| - Overactive bladder             | 624 (82%)   |
| - Prolapse                       | 335 (44%)   |

|   |             |
|---|-------------|
| - Bladder pain                                      | 1 (0.1%)    |
| Parity (median, interquartile range)                | 2 (2-3)     |
| Vaginal delivery [number (%)]                       | 679 (89.2%) |
| Previous hysterectomy [number (%)]                  | 248 (32.6%) |
| Previous continence / prolapse surgery [number (%)] | 156 (20.5%) |
| Pelvic organ prolapse (Stage 2+) [number (%)]       | 379 (49.8%) |
| Levator avulsion injury [number (%)]                | 158 (20.8%) |
| -Unilateral   | 91 (12%)    |
| -isolated right side                                | 74 (9.7%)   |
| -isolated left side                                 | 17 (2.2%)   |
| -Bilateral  | 67 (8.8%)   |

Table 1: Demographic data (n= 761)

#### Interpretation of results

We have previously shown that both rendered volumes and the visual assessment of tomographic ultrasound imaging of the pelvic floor can diagnose levator avulsion reproducibly, and this diagnosis has been validated against symptoms and signs of female pelvic organ prolapse. We have also shown that the distance between the centre of the urethra and the insertion of the puborectalis muscle, the 'levator- urethra gap' (LUG), is strongly associated with the diagnosis of avulsion (3). However, neither of those diagnostic criteria lends itself to automation with the help of simple pattern recognition algorithms. For this reason we obtained baseline data for unilateral hiatal width that could be employed in such algorithms. We have shown that levator avulsion injury is associated with a significant increase in unilateral coronal diameter of the levator hiatus, when measured during a pelvic floor muscle contraction. A cut-off level of 2.3 cm performs similarly to a LUG of 2.5 cm and demonstrated good sensitivity and specificity for the diagnosis of levator avulsion. This makes it a potentially useful diagnostic parameter for the automated detection of levator trauma.

#### Concluding message

Levator avulsion injury is associated with a significant increase in unilateral coronal diameter during PFMC on axial plane ultrasound of the pelvic floor in the plane of minimal dimensions. A cut off level of 2.3 cm has a sensitivity of 71% and specificity of 79% in predicting the diagnosis of levator avulsion injury by translabial ultrasound imaging. It is hoped that this parameter will allow automated detection of avulsion by pattern recognition algorithms.

#### References

1. BJOG 2008; 115: 979-84
2. Ultrasound Obstet Gynecol 2007; 29: 329-34
3. Ultrasound Obstet Gynecol 2008; 32: 941-945

|  |   |
|--|---|
| <b><i>Specify source of funding or grant</i></b>                             | <b>None</b>                               |
| <b><i>Is this a clinical trial?</i></b>                                      | <b>Yes</b>                                |
| <b><i>Is this study registered in a public clinical trials registry?</i></b> | <b>Yes</b>                                |
| <b><i>Specify Name of Public Registry, Registration Number</i></b>           | <b>WAHS HREC,<br/>file number 05-029.</b> |
| <b><i>What were the subjects in the study?</i></b>                           | <b>HUMAN</b>                              |
| <b><i>Was this study approved by an ethics committee?</i></b>                | <b>Yes</b>                                |
| <b><i>Specify Name of Ethics Committee</i></b>                               | <b>WAHS HREC,<br/>file number 05-029.</b> |
| <b><i>Was the Declaration of Helsinki followed?</i></b>                      | <b>Yes</b>                                |
| <b><i>Was informed consent obtained from the patients?</i></b>               | <b>Yes</b>                                |