



## AIMS OF STUDY

The posterior urethral valve is one of the most serious diseases in children with congenital lower urinary tract obstruction, accounting for 9% of neonatal urinary tract obstruction, only occurs in men, the incidence rate is 1 / 4000 ~ 1 / 8000<sup>[1-2]</sup>. Due to posterior urethral valves can lead to stunted growth and other urinary system and dysfunction, early diagnosis and treatment is particularly important<sup>[3-5]</sup>.

In this study, retrospective analysis was performed on the preoperative ultrasound findings, urinary cystoscopy results and resection records of posterior urethral valve in 20 children , which is in order to improve the ultrasound diagnosis value of posterior urethral valve.

## METHODS

**From January 2010 to March 2018**, 20 cases of posterior urethral valve were diagnosed by urethral cystoscopy, which all got valve resection and preoperative ultrasound exam. All cases were male, aged from 1 day to 10 years old which including 17 cases were younger than 1 years old and other 3 cases were older than 1 years old.

**symptoms:** Prenatal ultrasound diagnosed of urinary abnormality (hydronephrosis, ureteral dilatation, abnormal urethral echo mass) in 12 cases, urinary tract infection in 4 cases, difficulty in urination in 2 cases, tiny urine flow in 1 case, urinary incontinence in 1 case.

**Instruments:** GE VOLUSON E8 and MINDRAY DC-8 Color Doppler Ultrasound System. Convex array probe (frequency of 6-8 MHz) and high-frequency linear array probe (frequency of 8-12 MHz) were used for combined scanning.

### Surgery method:

1. 20 cases of posterior urethral valve were diagnosed by urethral cystoscopy, which all got valve resection.
2. Bilateral ureter anti-reflux replantation in 14 of 20 patients.

## RESULTS

**1.20 cases of posterior urethral valve were diagnosed by preoperative ultrasound in 14 cases.** The sonogram showed posterior urethral dilatation, irregular bladder neck thickening, bilateral hydronephrosis and bilateral ureteral dilatation, bladder wall thickening and trabecular formation. Five of the posterior urethral dilatations showed a strip-like echogenic membrane-like structure or a ratchet-like echo that protruded from the urethral sidewall into the urethral lumen.

**2. Ultrasound showed 4 cases of lower urinary tract obstruction.** The sonogram showed hydronephrosis, ureteral dilatation and thickening of the bladder wall, but did not show posterior urethral dilatation and valve structure.

**3. Ultrasound was misdiagnosed as neurogenic bladder in 2 cases.**

**4.20 patients were Confirmed diagnosis by urethral urethroscopic resection and urethral valve resection which including 18 cases of type I valve and 2 case of type III valve.**

## CONCLUSIONS

Ultrasound examination of urethra is simple and non-radioactive, which is not only can display urethra in real time, but also visualize the valve structure, and can simultaneously evaluate the kidney, ureter and bladder, without interventional procedures such as catheterization. Ultrasound is suitable for any age , especially for neonatal. It can be used as the first choice for imaging diagnosis of posterior urethral valve in children. Posterior urethral dilatation and urination experiments identify valve structures, irregular thickening of the bladder wall, trabecular formation, hydronephrosis and ureteral dilatation are the main points of ultrasound diagnosis of the posterior urethral valve.

## REFERENCES

- 1.Diamond D A, Chan I, Holland A, et al. Advances in paediatric urology.[J]. Lancet, 2017, 390(10099):1061-1071.
- 2.Toiviainen-Salo S, Garel L, Grignon A, et al. Fetal hydronephrosis: is there hope for consensus?[J]. Pediatric Radiology, 2004, 34(7):519-529.
- 3.Odeh R, Noone D, Bowlin P R, et al. Predicting risk of chronic kidney disease in infants and young children with posterior urethral valves at time of diagnosis: Objective analysis of initial ultrasound kidney characteristics and validation of parenchyma area as forecasters of renal reserve.[J]. Journal of Urology, 2016, 196(3):862-868.
- 4.Hochart V, Lahoche A, Priso R H, et al. Posterior urethral valves: are neonatal imaging findings predictive of renal function during early childhood?[J]. Pediatric Radiology, 2016, 46(10):1-6.
- 5.Nef S, Neuhaus T J, Spartà G, et al. Outcome after prenatal diagnosis of congenital anomalies of the kidney and urinary tract[J]. European Journal of Pediatrics, 2016, 175(5):667-676.

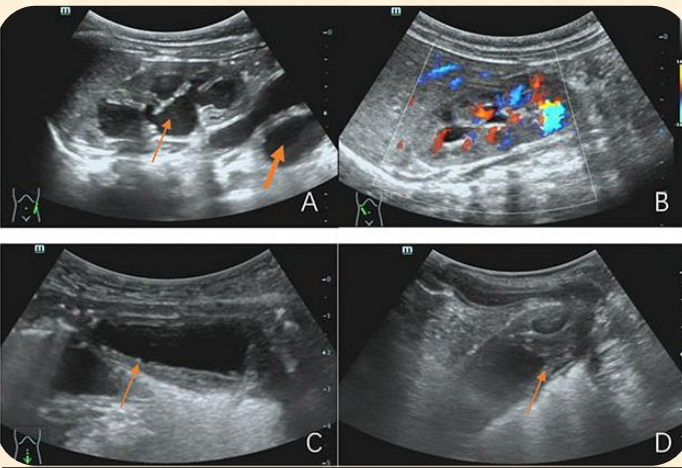


Figure 1 Ultrasound characteristics of posterior urethral valve in children: Case 1, male, 1 day, prenatal ultrasound diagnosed bilateral hydronephrosis and bilateral ureteral dilatation.

A and B: long axis view of the kidneys showed bilateral hydronephrosis, GRIGNON 4 level (thin arrows), bilateral ureteral dilatation (thick arrow); C: long axis view of the bladder showed irregular thickening of the bladder wall, less smooth and trabecular echo (arrow); D: lithotomy position, urethral long axis view showed irregular urethral dilatation (solid arrow), irregular neck thickening (dashed arrow).

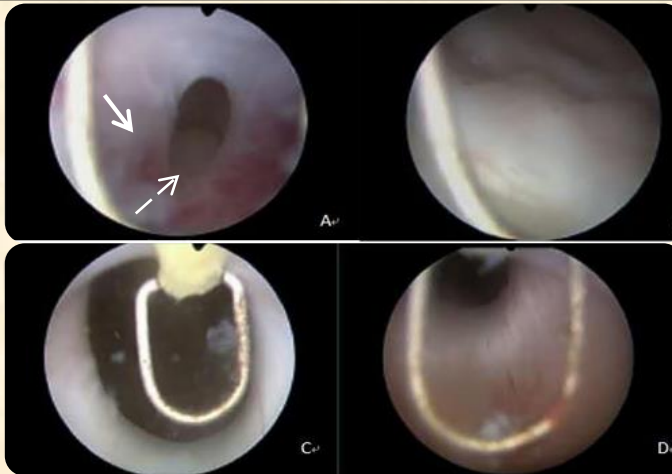


Figure 2 Pediatric urethroscopic cystoscopy and posterior urethral valve resection A: Urethral cystoscopy shows posterior urethral fine distal white valve structure, ring-shaped (solid arrow), small hole in the middle (dashed arrow), urethral lumen Here narrowed, through the urethra through the valve, the proximal urethra showed dilatation; B: thickening of the bladder wall, trabecular formation, bladder fibrosis; C: urethral valve resection using cold knife electrocoagulation; D: after The urethral constriction is relieved after valvectomy. The results of urethroscopic cystoscopy and urethral valve resection are consistent with preoperative ultrasound diagnosis (Figure 1);