

How to prevent neovesico-vaginal fistula in female ileal orthotopic neobladder surgery: Autologous peritoneal fascia graft interposition

Shin J, Lee D

Urology Institute, Ewha Womans University Mokdong Hospital

Introduction

Ileal orthotopic neobladder (IONB) following RC (radical cystectomy) requires discrete anatomical and functional reconstruction of lower urinary tract system to enable adequate voiding. Postoperative complications for female neobladder patients differ from those in males; females are more vulnerable to voiding dysfunction such as urinary retention requiring intermittent catheterization or urinary incontinence, and possibility of neovesico-vaginal fistula (nVVF). Various attempts to prevent nVVF have not been performed, but none of them was satisfactory enough to eliminate the incidence of nVVF. Here, we introduce the autologous peritoneal fascia graft interposition as a potential preventive method for nVVF by analyzing the predictive factors for fistula occurrence in female IONB patients.

Methodology

Study design

Female patients who underwent RC and IONB between January 2010 and December 2022 were included. Those with insufficient medical records or development of nVVF due to cancer recurrence at pelvic cavity were excluded from the analysis. Baseline oncological demographics and the incidence of nVVF were compared between peritoneal fascia graft group and the control.

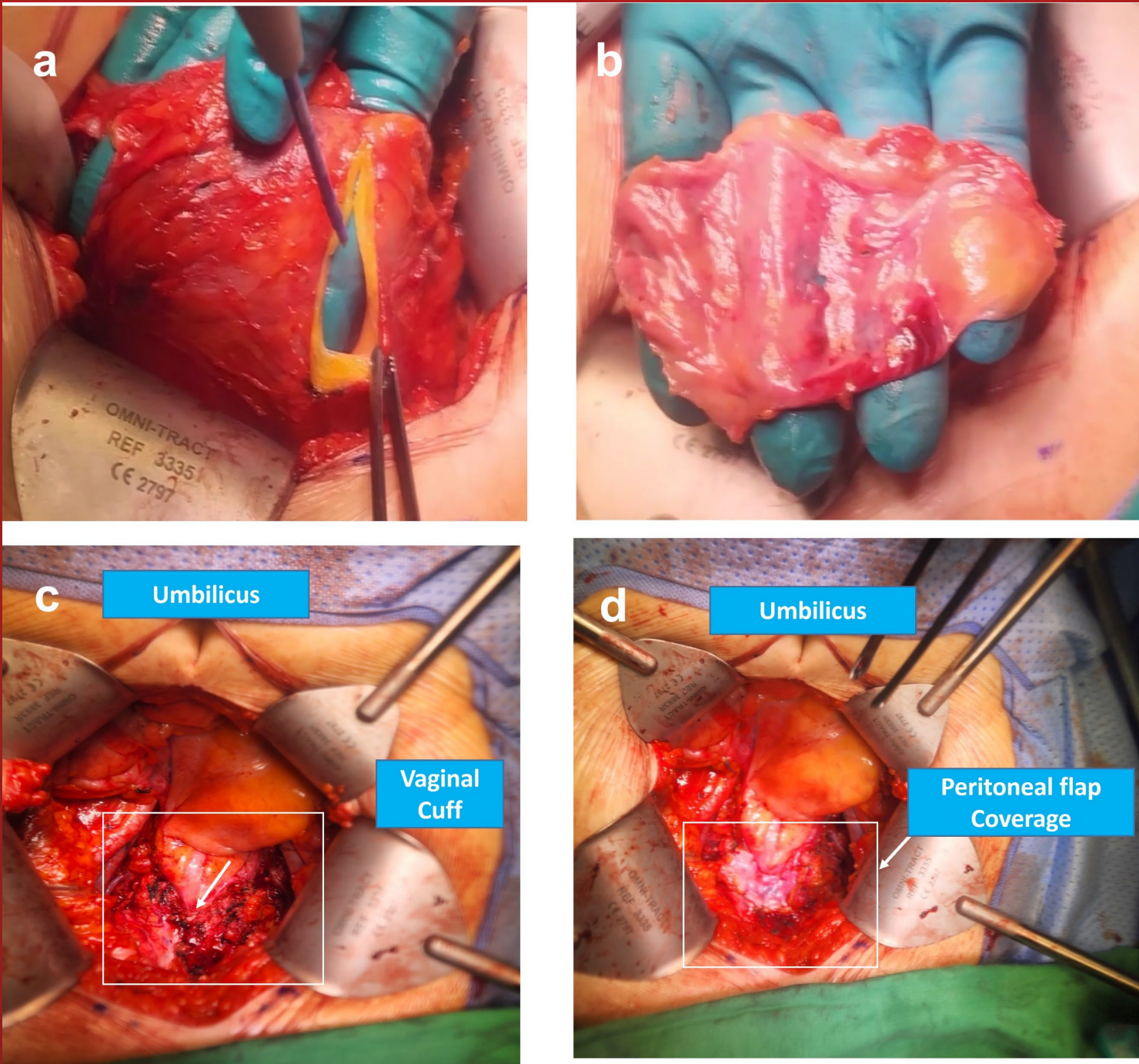
Surgical technique

I. Overall surgical process

Surgical procedures for radical cystectomy and ileal orthotopic neobladder were practically uniform in all patients; Initially, bilateral pelvic lymph node dissection and ureter ligation was performed via extraperitoneal approach. Next, peritoneum was opened to dissect posterior and bilateral pedicles of the urinary bladder and uterus. Then, radical cystectomy with or without hysterectomy (depending on surgical history) was performed. In cases with previous hysterectomy Finally, Studer-type ileal orthotopic neobladder was created.

II. Peritoneal fascia graft interposition

In cases of autologous peritoneal fascia graft interposition, the peritoneum was harvested at the time of peritoneal opening in rectangular shape (Figure 1a). The size was approximately 5cm x 5cm which is large enough to cover the vaginal cuff. Harvested peritoneal flap (Figure 1b) was preserved in 0.9% normal saline during radical cystectomy. After meticulous bleeding control, the graft was anchored on the surrounding tissue of vaginal cuff (Figure 1c) with 3-0 Monocryl(R) (J and J Medical; Polyglactin) just before bowel manipulation for neobladder creation. Vaginal cuff was successfully covered with peritoneal fascia graft (Figure 1d).

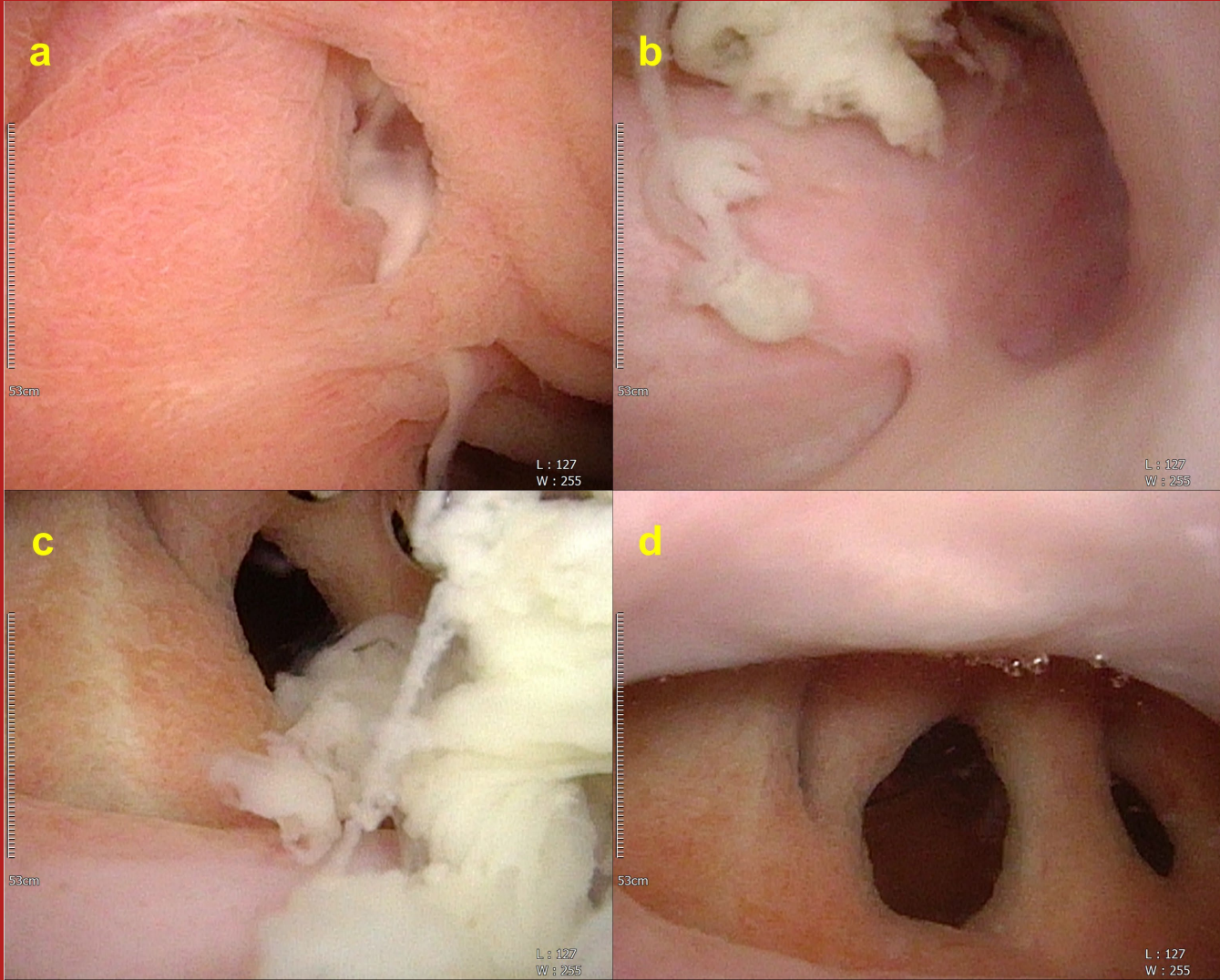


Acknowledgements

1. Shen J, Song ZQ, Shen HS, Li CF, Ruan YM, Li SW. [Transplantation of Autologous Peritoneum Using Ileal Seromuscular Flaps for Orthotopic Neobladder Reconstruction]. Zhongguo Yi Xue Ke Xue Yuan Xue Bao. 2020;42(4):497-503.
2. Shen J, Wu JF, Weng Y, Ruan YM, Li SW. [The mechanism and role of autologous peritoneum transplantation to enterocystoplasty in porcine model]. Zhonghua Yi Xue Za Zhi. 2019;99(46):3652-3656.
3. Wagner J, McLaughlin T, Pinto K, Tortora J, Gangakhedkar A, Staff I. The Effect of a Peritoneal Iliac Flap on Lymphocele Formation After Robotic Radical Prostatectomy: Results From the PLUS Trial. Urology. 2022.

Results

A total of 175 female patients (control; n = 118, peritoneal graft; n = 57) with IONB were included. The mean age of the include patients were 63.9 ± 10.1 years with median follow-up of 31.3 (0.7 – 131.2) months. More patients in the peritoneal graft group received neoadjuvant chemotherapy previously to RC than control (40.4% vs. 20.3%, p=0.005). The overall incidence of nVVF was 14.9% and identification of fistula was median of 2.9 (0.3 – 8.4) months. The nVVFs were observed 24 patients (20.3%) in the control group with conventional surgical technique and two patients (3.5%) in peritoneal graft group (p=0.003). In multivariate analysis, the risk factors for nVVF were old age (OR 1.050; 95% CI: 1.001 - 1.101, p=0.045) and neoadjuvant chemotherapy (OR 4.031; 95% CI: 1.448-11.219, p=0.008) and preventive factor for nVVF was peritoneal fascia graft interposition (OR 0.094; 95% CI: 0.020-0.439, p=0.003). The clinical course and feature of nVVFs in two patients of peritoneal fascia graft group differed from those in control. All patients in control did not suffer from continuous urine leakage from the ileal neobladder; two patients experienced transient urine leakage but complete healing of neobladder was finally confirmed. However, visible neobladder defects following the suture lines were observed in the nVVF patients of peritoneal group that peritoneal fascia graft was not identified on pre-fistula repair cystoscopy and vaginoscopy (Figure 2)



Conclusion

Interpretation of Results

The overall incidence of nVVF in current study was 14.9% which is higher than the literature. This discrepancy might result from increased utilization of neoadjuvant chemotherapy in bladder cancer patients as majority of publications analyzed patients who underwent RC before 2016 when neoadjuvant chemotherapy was not robustly applied. The abrupt increase of nVVF after increased utilization of neoadjuvant chemotherapy motivated developing alternative surgical technique to reduce such complication. Consequently, we replaced conventional non-replacement or fibrin patch or omental flap utilization to autologous peritoneal fascia graft interposition between neobladder and vaginal cuff. The advantages of autologous free peritoneal graft are that peritoneum it a simple structure with plenty of amount available in the abdominal cavity. Peritoneal graft can be applied in all cases except for those with inflammatory or malignant peritoneal diseases. Peritoneal graft prevents this abnormal re-epithelialization between two surfaces by directly covering the overlapping suture lines between ileal neobladder and vagina. The mechanism of nVVF formation in peritoneal graft group might be different from that of conventional groups. Continuous urine leakage from the neobladder defect despite prolonged Foley catheterization and bilateral percutaneous nephrostomy indwelling resulted in chronic inflammation which hindered normal healing of both neobladder and vaginal wall. Consequently, fistulous tract was observed elsewhere from peritoneal flap. Alongside neoadjuvant chemotherapy and peritoneal fascia graft interposition, age was also associated with increased risk of nVVF formation. The negative impact of aging has been previously discussed in other operations as well. As old age is also associated with increased anesthesia risks, bladder preservation strategy with maximal transurethral resection of bladder tumor with concurrent chemotherapy and radiation therapy should be actively considered for those who are vulnerable to operation

Concluding message

Autologous peritoneal fascia graft interposition between vaginal stump and neobladder is a promising technique to prevent nVVF in female IONB surgery. Old age and neoadjuvant chemotherapy might pose negative impact on healing process of female IONB. Increased risks of nVVF should be counselled thoroughly especially in old female bladder cancer patients who underwent neoadjuvant chemotherapy. Especially in such settings, autologous peritoneal fascia graft interposition between vaginal stump and neobladder could be a promising option to reduce the nVVF formation in female IONB surgery.