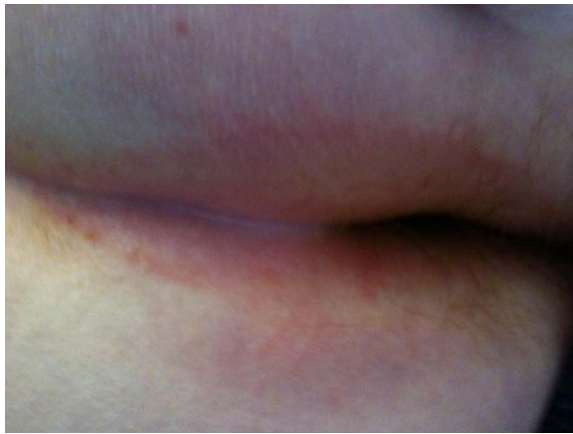
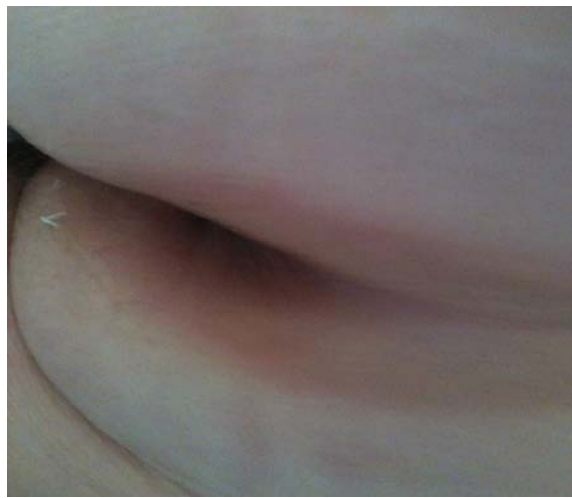
Redness and Incontinence Associated Dermatitis


The skin damage of inflammation from Incontinence associated dermatitis (IAD) appears as redness that can vary in shade from light pink to bright red. In darker-toned skin, inflammation may appear as redness or as patches of darker or lighter coloring. Damaged skin may also look shiny and wet, with local swelling or fluid buildup. A fungal (yeast) infection can develop in IAD and appears as a rash. Flaking of skin may develop as the infection heals. IAD can develop in any body area exposed to leaked feces or feces and urine but most often occurs around the anal opening and between and on the buttocks



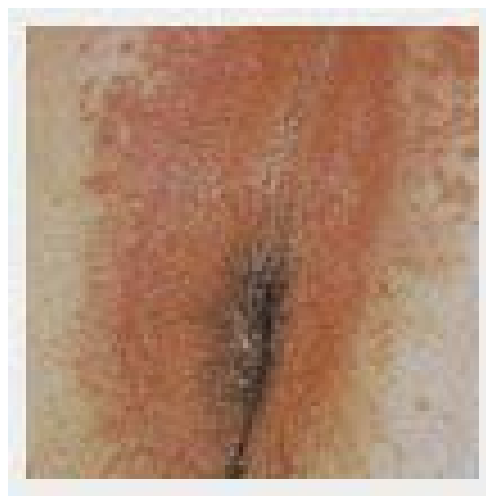IAD in between and outside of the buttocks



IAD in between and outside of the buttocks



IAD in between and outside of the buttocks



IAD and rash of fungal infection

Incontinence can damage the top layers of skin and make the skin more at risk for damage from pressure and shearing (sliding) forces. The damage is usually over a bony area and often appears as a defined open area. It can worsen to become a larger wound.

Pressure Ulcer Wounds:

