

Artificial Urinary Sphincter: Report of the 2015 Consensus Conference

X. Biardeau, S. Aharony, the AUS Consensus Group,* L. Campeau, and J. Corcos**
Department of Urology, Jewish General Hospital, McGill University, Montreal, Québec, Canada

Purpose: The AMS800™ device, by far the most frequently implanted artificial urinary sphincter (AUS) worldwide, is considered to be the “gold-standard” when male incontinence surgical treatment is contemplated. Despite 40 years of experience, it is still a specialized procedure with a number of challenges. Here, we present the recommendations issued from the AUS Consensus Group, regarding indications, management, and follow-up AMS800™ implantation or revision. **Materials and Methods:** Under ICS auspices, an expert panel met on July 10, 2015 in Chicago, IL, USA in an attempt to reach a consensus on diverse issues related to the AMS800™ device. Participants were selected by the two co-chairs on the basis of their practice in a University hospital and their experience: number of implanted AUSs according to AMS (American Medical System Holdings Inc., Minnetonka, MN) records and/or major published articles. Topics listed were the result of a pre-meeting email brainstorming by all participants. The co-chairs distributed topics randomly to all participants, who then had to propose a statement on each topic for approval by the conference after a short evidence-based presentation, when possible. **Results:** A total of 25 urologists were invited to participate, 19 able to attend the conference. The present recommendations, based on the most recent and relevant data available in literature as well as expert opinions, successively address multiple specific and problematic issues associated with the AMS800™ through a eight-chapter structure: pre-operative assessment, pre operative challenges, implantation technique, post-operative care, trouble-shooting, outcomes, special populations, and the future of AUSs. **Conclusion:** These guidelines undoubtedly constitute a reference document, which will help urologists to carefully select patients and apply the most adapted management to implantation, follow-up and trouble-shooting of the AMS800™. *Neurourol. Urodynam. 35: S8–S24, 2016.* © 2016 Wiley Periodicals, Inc.

Key words: International Continence Society; guidelines; AMS800

Conflict of Interest: Dr. Morey has received honoraria from Coloplast and American Medical Systems outside the submitted work. Dr. Mourtzinou has served as a consultant for Boston Scientific, Medtronic, Allergan, and Astellas outside of the submitted work. Dr. Peterson has received grants from American Medical Systems and Coloplast during the conduct of the study, as well as grants from American Medical Systems outside of the submitted work. Dr. Chartier-Kastler reports personal fees from American Medical Systems and personal fees from Uromedica outside of the submitted work. Dr. Sandhu reports personal fees from Boston Scientific outside the submitted work. Dr. Corcos reports grants from Pfizer, Astellas, and Allergan outside the submitted work. Dr. Angermeier reports grants and personal fees from American Medical Systems (now Boston Scientific) outside the submitted work. Dr. McCammon has received honoraria from American Medical Systems and has been a consultant for American Medical Systems outside the submitted work. Dr. Drake reports grants, personal fees and non-financial support from Allergan, grants and personal fees from Ferring, grants, personal fees and non-financial support from Astellas, outside the submitted work. Dr. Westney reports grants from American Medical Systems, outside the submitted work. Dr. Herschorn reports personal fees from Boston Scientific, during the conduct of the study; grants and personal fees from Astellas, grants and personal fees from Allergan, personal fees from Pfizer, personal fees from Merus, personal fees from Lilly, personal fees from Promedon, outside the submitted work. Dr. Boone has served on advisory boards and acted as a speaker for Astellas and Allergan outside of the submitted work. Dr. Nitti has served as an investigator for Allergan, Astellas, and Cook MyoSite outside of the submitted work. Dr. Brant reports grants and personal fees from Boston Scientific, during the conduct of the study. Dr. Hellstrom reports personal fees from American Medical Systems, during the conduct of the study; personal fees from Abbvie, Allergan, Antares, Astellas, Coloplast, Endo, Pfizer, Repros, Lipocine, other from Coloplast, Endo, NERI, personal fees from Endo, Menarini, other from NIH, Theralogix, outside the submitted work. The other authors have no conflicts to disclose.

Abbreviations: AUS, artificial urinary sphincter; BOO, bladder outlet obstruction; ICS, International Continence Society; IPP, inflated penile prostheses; ISD, intrinsic sphincter deficiency; LUT, lower urinary tract; OAB, overactive bladder; PN, perineal; PP, penile prosthesis; PPI, post-prostatectomy incontinence; PRB, pressure-regulating balloon; PSA, prostate-specific antigen; PVR, post-void residual; RCT, randomized clinical trial; SUI, stress urinary incontinence; TA, tunica albuginea; TC, trans-corporal; TS, trans-scrotal; UDS, urodynamic studies; UI, urinary incontinence; UTI, urinary tract infection.

*The AUS Consensus Group: KW Angermeier¹, TB Boone², WO Brant³, E Chartier-Kastler⁴, DS Elliott⁵, M Drake⁶, WJ Hellstrom⁷, S Herschorn⁸, JS Sandhu⁹, KA McCammon¹⁰, AF Morey¹¹, A Mourtzinou¹², VW Nitti¹³, AC Peterson¹⁴, OL Westney¹⁵, FA Yafi⁷

¹Glickman Urologic and Kidney Institute, Cleveland Clinic Foundation, Cleveland, OH, USA

²Department of Urology, Houston Methodist Hospital, Houston, TX, USA

³Division of Urology, Center for Reconstructive Urology and Men's Health, University of Utah, Salt Lake City, UT, USA

⁴Pitié-Salpêtrière Academic Hospital, Department of Urology, Assistance Publique-Hôpitaux de Paris, Pierre and Marie Curie Medical School, Paris, France

⁵Department of Urology, Section of Pelvic and Reconstructive Surgery, Mayo Clinic, Rochester, MN, USA

⁶Bristol Urological Institute, University of Bristol, Bristol, UK

⁷Department of Urology, Tulane University Health Sciences Center, New Orleans, LA 70112, USA

⁸Division of Urology, Sunnybrook Health Sciences Centre, University of Toronto, Toronto, ON, Canada

⁹Division of Urology, Department of Surgery, Memorial Sloan Kettering Cancer Center, New York, New York, USA

¹⁰Department of Urology, Eastern Virginia Medical School, Norfolk, VA, USA

¹¹Department of Urology, University of Texas Southwestern, Dallas, TX, USA

¹²Institute of Urology, Lahey Clinic Medical Center, Tufts University School of Medicine, Burlington, MA 01805, USA

¹³Department of Urology, New York University Langone Medical Center, New York, New York, USA

¹⁴Division of Urologic Surgery, Department of Surgery, Duke University Medical Center, Durham, NC, USA

¹⁵Division of Urology, Department of Surgery, University of Texas-Houston Medical School, Houston, TX 77030, USA

**Correspondence to: Jacques Corcos, MD, Department of Urology, Jewish General Hospital, 3755 chemin de la Côte Sainte-Catherine, Montreal, Quebec, Canada H3T 1E2.

E-mail: jcorcos@uro.jgh.mcgill.ca

Published online in Wiley Online Library

(wileyonlinelibrary.com).

DOI 10.1002/nau.22989

INTRODUCTION

The AMS800™ device, by far the most frequently implanted artificial urinary sphincter (AUS) worldwide, is considered to be the “gold-standard” when male incontinence surgical treatment is contemplated. Despite 40 years of experience, it is still a specialized procedure with a number of challenges. In an attempt to provide urologists with clear and concise guidelines regarding AMS800™ implantation or revision, an expert consensus panel (The AUS Consensus Group) met on July 10, 2015 in Chicago, IL, USA. The following guidelines mainly focus on post prostatectomy male incontinence and are based on the most recent and relevant data available in the literature as well as expert opinions on the topic. The present statements aim to guide urologists in carefully selecting patients and applying the most appropriate treatment as well as follow-up procedures—to deal with specific or problematic cases involving the AMS800™. Because very little literature and no high level of evidence exist with any other AUS device, only the AMS800™ was considered during this conference.

MATERIALS AND METHODS

The present consensus conference was initiated by the two co-chairs, J Corcos and L Campeau, who selected participants with the most extensive experience: number of implanted AUSs according to AMS (American Medical System Holdings Inc., Minnetonka, MN) records and major published articles—with practice in university teaching hospitals. A few other European surgeons were contacted but were unable to attend at the chosen date. Of the 25 urologists invited to participate, 19 participated in the conference. The topics listed were the result of pre-meeting email brainstorming by all participants. The co-chairs distributed topics randomly, with the exception of “AUS in women,” a topic in which only one participant had wide experience. For each topic participants had to prepare a statement for approval by the conference after a short presentation based on evidence, when possible. The International Continence Society (ICS) took charge of all conference logistics thanks to an unrestricted grant from AMS.

RESULTS

Eight main chapters were identified: pre-operative assessment, pre-operative challenges, implantation technique, post-operative care, troubleshooting, outcomes, special populations, and the future of AUSs. We present approved statements for each domain when “absolute consensus” or “majority consensus” was reached, along with evidence supporting it. The grade of recommendation associated with each statement was also reported according to the Oxford Centre for Evidence-based Medicine.

Preoperative Assessment

Patient selection. The AUS should be offered to individuals with stress urinary incontinence (SUI) due to intrinsic sphincter deficiency (ISD), who have failed conservative management. Patients must present sufficient dexterity and cognitive function to operate the device. (*Grade of recommendation A*)

Urinary incontinence (UI) can occur in men after prostate surgery of benign or malignant conditions, secondary to bladder dysfunction and/or ISD arising from iatrogenic injury to the urethral sphincter muscle or its innervation.¹

Conservative management should be offered as a first line treatment to all men SUI related to ISD, such as behavioral interventions and pelvic floor muscle training in a defined program under the supervision of qualified physiotherapists. These modalities accelerate recovery from incontinence after prostatectomy and increase the continence rate after 1 year.²

Surgical management can be offered to men with ISD-associated SUI when it significantly impacts their quality of life and they have failed conservative treatment. The current surgical options are different commercial types of male perineal slings and the AMS800™. Although no results are currently available from randomized clinical trials (RCTs) comparing these techniques head to head, their clinical outcomes have been reported to vary according to the severity of incontinence. Fortunately, such RCTs are being conducted in the U.K., and the data are awaited (<http://www.controlled-trials.com/ISRCTN49212975>).

AUS implantation requires adequate manual efficiency and dexterity in patients, as well as intellectual ability and adequate cognitive function for safe and proper use.³

Clinicians should consider AUS placement no earlier than 6 months after prostatectomy if patients are incontinent and not improving. (*Grade of recommendation C*)

There are no clear data and, as such, no existing guidelines on the timing of AUS placement for the management of SUI caused by treatment of benign or malignant prostate disease. Observational studies of men after radical prostatectomy for prostate cancer typically demonstrate improvement in continence until 1 year after surgery,⁴ with a continence plateau achieved after 12 months.^{5,6} Lepor and Kaci⁷ noted a slight increase in continence rates, from 95.2% to 98.5%, 12 to 24 months after radical prostatectomy. Based on these findings, it has been traditionally recommended that AUS placement be deferred during the first year after prostate cancer surgery. However, Smither et al.,⁸ using a standardized measure of incontinence (1-hr pad test), found that 18 weeks appeared to be the time point after which most patients achieved control. Similarly, Goluboff et al.⁹ resolved that 92% of their patients reached their final continence status at 6 months.

Several authors have established the importance of continence stability as a factor in determining if surgical intervention is appropriate.¹⁰ It is the consensus opinion of the panel that patients with bothersome, severe symptoms (e.g., gravitational incontinence), without any apparent improvement at 6 months after surgery for benign or malignant prostate disease, are not likely to experience a satisfactory level of continence over time with continued conservative management or observation. Thus for patients with severe incontinence that is not improving, AUS placement may be considered, beginning at 6 months, and patients should be informed that spontaneous improvement could still occur. However, if continence is still improving, even at 12 months, it may be prudent to delay surgical therapy somewhat longer, at the surgeon's discretion.

Patient evaluation. SUI should be evaluated and verified by careful history, physical examination, or other objective tests. (*Grade of recommendation D*)

Despite the lack of formal evidence regarding their effects on outcomes, there is universal agreement that history-taking and physical examination should be the first step in the assessment of anyone with UI.¹¹ Patient history should focus on the characterization of incontinence (stress- or activity-related vs. urgency), its severity and progression or resolution

over time. Specifically, patients should be questioned about what precipitates leakage—straining, walking, coughing, exercise, etc., suggestive of SUI or sudden onset of the sense of needing to void immediately, particularly in the absence of any physical activity, indicative of urgency urinary incontinence.

American Urological Association Guidelines on the Surgical Management of Female SUI state that the objective demonstration of SUI should be confirmed prior to surgical management,¹² and recommends that the presence of SUI be confirmed objectively prior to AUS placement. This may be done by simple physical examination, provocative testing (e.g., bending, shifting position, stress pad testing) or urodynamic studies (UDS).

UDS should be carried out at the discretion of clinicians in cases where it will help with diagnosis or counseling and follow-up. Poor bladder compliance may pose a risk of upper tract damage after AUS placement and should be followed closely. (*Grade of recommendation C*)

UDS remain invaluable in the diagnosis of incontinence type in patients post-prostatectomy. However, it is not always a requirement in the setting of male SUI. Complaints of involuntary leakage on effort or exertion, or on sneezing or coughing (i.e., symptoms of SUI) are highly correlated with urodynamic stress incontinence.¹³

No controlled studies have assessed the value of UDS versus no UDS in men with SUI. UDS may be helpful to diagnose bladder dysfunction, such as detrusor overactivity or decreased compliance and bladder capacity as well as to assess sphincteric function with the determination of abdominal leak point pressure (ALPP). However, none of these parameters has been shown to affect outcomes following AUS placement.^{14–17} Furthermore, ALPP does not correlate well with the degree of UI, as determined by the 24-hr pad test.¹⁶ However, if clinicians are unsure of whether sphincteric versus bladder dysfunction is the cause of UI, or if there is unexplained poor bladder emptying, UDS may be helpful in providing that additional information.

UDS will undoubtedly find its place in patients at risk of impaired bladder compliance, such as those who have had pelvic radiation or suffer from neurogenic lower urinary tract (LUT). The observation that poor bladder compliance did not worsen AUS continence outcomes may actually be an “ominous” sign, as increasing outlet resistance could potentially expose the upper tract to even higher intra-vesical pressures.¹⁷ Although this risk has been well documented in pediatric patients with myelomeningocele,^{18–21} it is not known if poor bladder compliance and uncorrected storage pressure are absolute contraindications to AUS implantation in patients with non-neurogenic SUI. Nevertheless, it is the opinion of the committee that such patients should be carefully followed to avoid a potentially devastating outcome of irreversible renal insufficiency with periodic upper urinary tract imaging and/or UDS.

Pre-operative endoscopic evaluation of the LUT is highly recommended prior to AUS placement as unrecognized urethral pathology can complicate surgical implantation and possibly affect expectations of long-term outcomes. (*Grade of recommendation D*)

Visual assessment of the membranous urethra, prostatic urethra (if present), and bladder neck is important prior to AUS placement. Pre-operative cysto-urethroscopy can verify the integrity of the distal sphincteric mechanism but, more importantly, allow the assessment of anastomotic stricture or bladder neck contracture that may require further treatment

either before or during AUS placement. Also, the bladder may be evaluated for any pathology that could affect AUS placement decisions (stone, tumors etc.). In cases where patients may be considering alternative treatment of incontinence, such as slings, cysto-urethroscopy may provide additional information to further strengthen the argument for AUSs—if scarring prevents adequate compression from a sling. This can improve informed decision between different surgical treatment options.¹⁰

In cases where pre-operative cysto-urethroscopy is not performed before surgery, it should be done at the start of AUS implantation, before any incision is made, and patients should be made aware of the potential consequences if significant urethral or bladder pathology is discovered.

Patient teaching. Pre-operative teaching must deliver a full explanation of device function, including typical time range of effective function. (*Grade of recommendation D*)

Pre-operative instruction is a central component of confirmation that patients are appropriate candidates for implantation. No studies have been designed to critically assess the key constituents of pre-operative teaching for AUS patients. Urological reviews focused on AUSs are primary mediums containing detailed information of the pre-operative counseling process.^{22,23} Considering that AUSs require ongoing patient participation to ensure proper function and are associated with finite lifespan as well as unique complications, patient comprehension is important prior to proceeding with surgery.

To ensure that patients have a sufficient understanding of device function, a complete description of AUS mechanics is suggested with a model or visual aid. This discussion should include: normal cycling, the role of deactivation, contra-indicated activities, and expected continence outcomes. Detailed pre-operative counseling gives patients realistic expectations of normal operation of the device. In addition, patients should be furnished with an estimate of expected AUS lifespan. Several large, long-term AUS series report device survivorship of 72–79% without revision at 5 years.^{24–26} Therefore, quoting a median lifespan of 5–7 years is consistent with the best available literature.

Patients must be informed about expected rates of mechanical failure, erosion and infection. (*Grade of recommendation D*)

Re-operation for any cause occurs in about 26% (range: 14.8–44.8) of patients.²⁷ Thus, patients must be fully informed of rates of mechanical failure, erosion and infection. The most problematic complications with respect to management and patient morbidity are erosion and/or infection. In many instances, the conditions may co-exist. Unlike corrections for mechanical failure, treatment of erosion and/or infection generally requires device removal resulting in resumption of pre-AUS incontinence levels. Depending on the overall clinical situation, the device may be replaced in 3–6 months after explantation.^{26,28} The fact that revisions do not result in diminished long-term patient satisfaction should be mentioned.²⁹

Preoperative Challenges

Bladder neck and vesico-urethral stricture. Clinicians must consider bladder neck or vesico-urethral anastomotic stricture prior to AUS placement. (*Grade of recommendation D*)

Anastomotic contractures may occur in 1.3–29% of patients after prostate cancer surgery and ablative therapies, such as

cryotherapy or radiation.^{30–32} The incidence may climb as high as 62% in patients who undergo radical prostatectomy after radiotherapy.³³ Seven to thirty percent of patients undergoing high-intensity focused ultrasound also may develop strictures after treatment.³² Strictures tend to develop within 24 months of prostate surgery but may occur at later times in those who have undergone radiation or other ablative therapies.³⁰ Risk factors for bladder neck strictures after prostate cancer therapy include: obesity, patient age, surgical volume of operating surgeon, blood loss at the time of prostatectomy, prostate cancer treatment modality (surgery, radiation, ablative therapy), cancer stage, prostate-specific antigen (PSA), type of reconstruction, postoperative urinary extravasation and prior endoscopic interventions. Bladder neck strictures can also occur after transurethral resection of the prostate for benign prostate hyperplasia (BPH) in 0.6–14% of patients.³⁴ All of them may be associated with varying degrees of SUI thus complicating AUS placement. Therefore, awareness of their presence is paramount to the successful management of urinary symptoms.^{35–37}

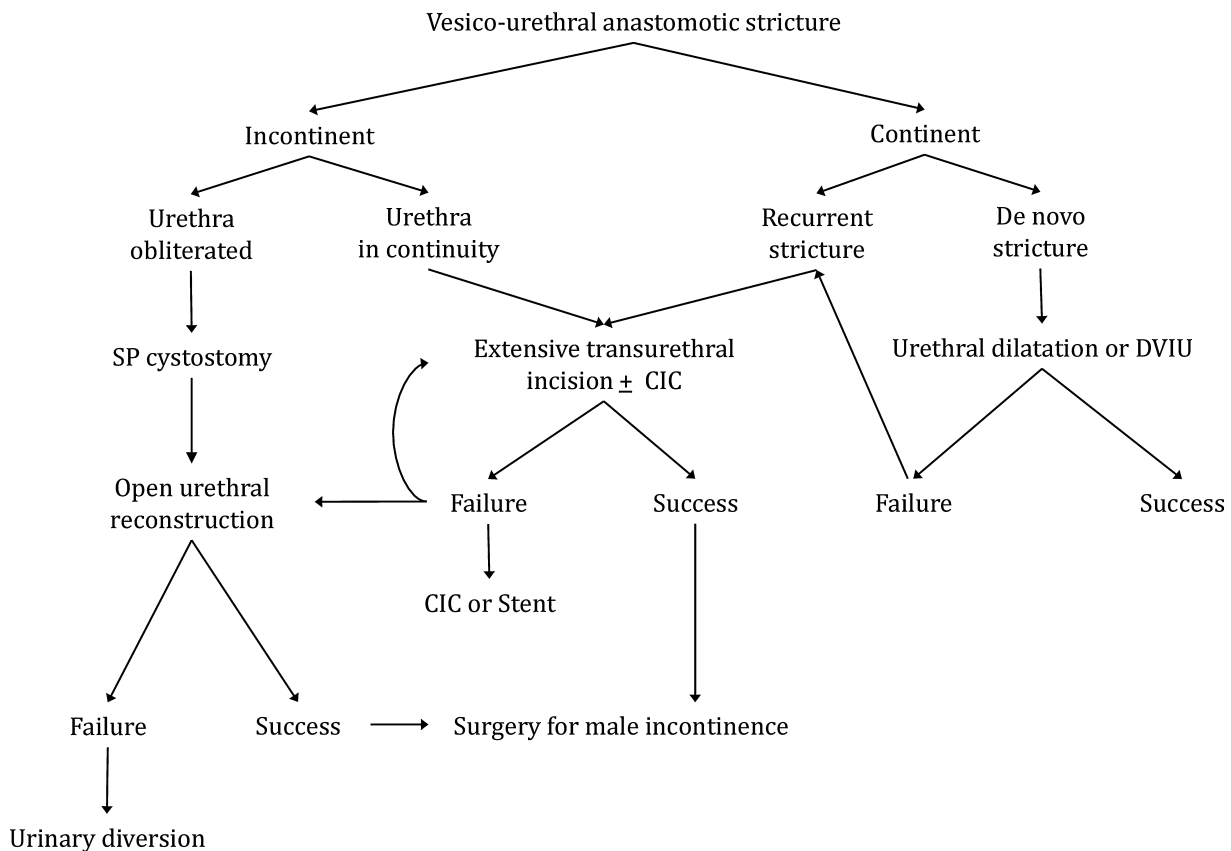
Strictures should be suspected in patients with decreased flow and incomplete emptying (flow test, post void residual [PVR]). Definitive diagnosis should be based on direct visualization with cysto-urethroscopy. (Grade of recommendation D)

Many patients with strictures present symptoms of decreased flow and incomplete emptying, in addition to SUI. Vesico-urethral anastomotic stricture and bladder neck

stenosis may be detected by history-taking and physical examination combined with uroflowmetry in most cases.^{32,38} However, the definitive diagnosis should be made by direct visualization with cysto-urethroscopy.³²

Surgeon must treat clinically relevant bladder neck or vesico-urethral anastomotic stricture either prior to or during AUS implantation. (Grade of recommendation D) (Fig. 1)

While, ideally, contractures should be treated and resolved prior to AUS placement to avoid the need for future instrumentation through the device with subsequent damage, they can be difficult to address because of aggressive recurrence despite seemingly appropriate initial management. Therefore, multiple techniques have been described in preparation for AUS placement, including staged and synchronous approaches.³⁹ Options to treat these strictures prior to AUS placement (staged approach) comprise open reconstruction,^{40–42} incision or dilation and stent placement.^{36,37,43} Transurethral resection of scar tissue is also frequently utilized. This procedure may be done prior to AUS placement, being followed by a period of several weeks to months of healing with re-evaluation by endoscopy to ensure stabilization of scar tissue prior to embarking upon AUS placement.^{39,44} There are also reports of managing strictures simultaneously (synchronous) with AUS placement in the same setting.⁴⁵ Internal urethrotomy and urethral dilation have reported success rates of 25–73% for bladder neck contracture after prostatectomy.^{35,46,47} Furthermore, up to 27% of cases may recur after



CIC: Clean Intermittent Catheterization; DVIU : Direct Vision Internal Urethrotomy; SP: Supra-pubic

Fig. 1. Proposed algorithm for vesico-urethral anastomotic stricture—ICUD 2014 (International Consultation on Urological Diseases, 2014).³²

2–3 or more dilations or incisions.⁴⁷ The recurrence rate is high also in the open repair group, ranging from 30% to 60% after major operative reconstruction.⁴² In some cases of recalcitrant strictures that recur continuously, patients may be relegated to intermittent calibration for extended periods of time. This intermittent calibration may be performed safely through AUSs in select instances.

The management of urethral and vesico-urethral anastomotic strictures encountered after AUS implantation poses a unique challenge. Strictures at the AUS cuff site may result from compression or ischemia and may indicate impending urethral erosion. These may be safely managed with careful periodic dilation through AUSs.⁴⁸ Management of recurrent bladder neck strictures proximal to AUSs after one is placed for SUI is a significant surgical task because instrumentation with an AUS in place may lead to increased risk of erosion. These patients often require multiple interventions with various outcomes. Despite these challenges, many authors have described the successful treatment of strictures proximal to AUSs with balloon dilatation⁴⁹ and laser incision through a small urethroscope.³⁹ In the event significant endoscopic manipulation and resection are required proximal to the cuff site, it is safest to consider surgically uncoupling of the cuff for the duration of the endoscopic procedure.

Pre-operative urinary tract infection (UTI) and pre-operative antibiotics. Pre-operative prophylactic antibiotics should be administered for all AUS procedures within 60 min of the incision. (*Grade of recommendation A*)

Excellent guidelines⁵⁰ and evidence support the use of prophylactic antibiotics at the time of urologic prosthetic surgery. Although there is not direct evidence about the use of prophylactic antibiotics at the time of AUS placement, proof can be found in the orthopedic and hernia literature that pre-operative antibiotics reduce the rate of surgical site infections.

All efforts should be made to ensure low bacterial counts at the time of AUS placement—through treatment of UTI or immediate pre-operative skin prep. (*Grade of recommendation B*)

All infection sites, including the urinary tract, should be treated before the procedure, to protect the operative field from potential bacterial contamination.⁵⁰ Skin bacterial counts should also be lowered with immediate pre-operative skin preparation as this has been shown to decrease bacterial colonization rate fourfold in a large cohort study.⁵¹

Radiation. Radiated patients should be informed that they constitute a high-risk population with increased adverse outcomes of AUS surgery and associated complications, including cuff erosion as well as re-operation. (*Grade of recommendation B*)

In the last 10 years, adjuvant radiation therapy has played an increasing role in the management of locally advanced prostate cancer. Pelvic radiation may be accompanied by subsequent development of fibrosis and chronic vascular damage in the targeted regions. Spongiosal atrophy may be expected in AUS patients who have been radiated. Increased rates of AUS re-operation and cuff erosion have been reported in many series,^{52–56} although not universally.²⁵ Despite the associated risks, AUS implantation in radiated patients is commonly undertaken and linked with significantly improved continence in the majority of patients. Because spongiosal atrophy is commonplace in radiated patients, many surgeons elect for

trans-corporal (TC) or 3.5-cm cuff placement to optimize AUS coaptation and prevent revision surgery.⁵⁷

When AUS implantation is considered in males presenting with post-prostatectomy incontinence (PPI), the potential indication for adjuvant radiation therapy should be taken into account, and risks and benefits of cancer control versus urinary outcome need to be weighed. (*Grade of recommendation D*)

There are no data to guide the decision of when to offer radiation therapy versus the timing of AUS placement surgery.⁵⁸ In general, cancer control is a primary concern which tends to be addressed by the initial oncology team promptly within months of radical prostatectomy, based on positive surgical margins and/or rising PSA values which tend to occur in the early post-operative period. Urinary continence may deteriorate after adjunctive radiation in some cases. Overall, radiation therapy is usually conducted long before the referral for anti-incontinence surgery.

Detrusor overactivity. Detrusor overactivity should be treated before surgery, but does not constitute a contraindication for AUS implantation. (*Grade of recommendation D*)

Overactive bladder (OAB) symptoms occur in up to 25% of post-prostatectomy patients. In these patients, an effort should be made to ascertain the underlying bladder dysfunction and consider a treatment whenever possible. In other words, UDS should be performed systematically to document the presence of detrusor overactivity (DO), impaired compliance or decreased bladder capacity. Even if none of these parameters has been shown to affect outcomes after AUS placement,^{14–17} the present expert consensus panel feels that it is of great importance to initially diagnose them—to treat the related symptoms before AUS implantation and be able to properly distinguish between initial and untreated bladder dysfunction and a device malfunction in months or years after implantation.

Moreover, patients with high filling pressures due to DO, decreased bladder capacity or impaired compliance might be exposed to a significant risk of upper urinary tract deterioration after urinary sphincter enforcement and the emergence of bladder outlet obstruction (BOO). Even if no data in the literature currently support this point, the expert consensus panel thinks that such a specific population should be properly treated and monitored closely with periodic upper urinary tract imaging and UDS.

Finally, even if patients with post-operative OAB (either de novo or persistent) do have increased incontinence compared to those without OAB,⁵⁹ the consensus expert panel suggests that patients with mixed UI still undergo AUS implantation, with correct treatment and adapted follow-up provided.

In practice, patients with initially elevated storage pressures could be treated pre-AUS implantation with anticholinergic drugs or intra-detrusor injection of onabotulinumtoxinA to lower pressures. UDS could then be repeated, distant from the treatment initiation, to document safe pressure restoration before AUS surgery.

Implantation Technique

Installation, scrubbing and draping. Surgery for AUS implantation may be performed either in lithotomy or supine position. (*Grade of recommendation D*)

In lithotomy, the patient is placed in stirrups with legs spread apart. The main benefit of this approach is the easy access to the

perineum. Special attention must, however, be paid to avoid compression of the common peroneal nerve between the lateral head of the fibula and the bar holding the legs as it can lead to post-operative foot drop.⁶⁰ Conversely, the supine position is preferred when opting for a trans-scrotal approach, or when there are contraindications to placing the patient in lithotomy. The addition of Trendelenburg table tilt may further aid in exposure and dissection. A modified version of the supine approach has been described and includes gently abducting the legs and slightly flexing the knees, with the surgeon standing between the patient's legs.⁶¹

Surgeons should be permitted their choice of razors or clippers for pre-operative preparation of the male genitalia. (*Grade of recommendation A*)

Hair removal is generally recommended in-hospital peri-operatively rather than by the patient prior to hospital presentation. With regard to hair removal, a Cochrane review of non-prosthetic surgery showed significantly more surgical site infections when patients were shaved with a razor rather than with clippers (RR 2.02, 95% CI 1.21–3.36).⁶² The skin of male genitalia is sensitive, irregular, and elastic which makes it ill-suited for clippers, which tend to produce multiple skin breaks (cuts, abrasions and scratches). In a prospective, randomized study of 215 patients (107 clipper, 108 razor) undergoing scrotal surgery, razor use resulted in significantly less skin trauma and a more complete hair removal within the surgical field ($P = 0.017$) compared to clippers.⁶³

Chlorhexidine-alcohol skin preparation is superior to povidone-iodine. (*Grade of recommendation A*)

Regarding skin preparation, available compounds currently include povidone-iodine and chlorhexidine-alcohol. Povidone-iodine works by damaging proteins and DNA via free iodine. Recommended scrub time is 5 min, followed by a painting process, then allowing the preparation to dry. This two-step approach typically takes 10 min.⁶⁴ Chlorhexidine-alcohol works by denaturation of proteins and disruption of cell membranes. Its onset of action is rapid and its antimicrobial properties persist for up to 48 hr. Owing to its potential flammability, it is recommended to proceed with a 2-min scrubbing followed by a 3-min drying period.⁶⁵

In a prospective, randomized study of 849 surgical patients, 14% of whom were urology cases, chlorhexidine-alcohol was significantly more protective than povidone-iodine against both superficial (4.2% vs. 8.6%, $P = 0.008$) and deep incisional infections (1% vs. 3%, $P = 0.05$).⁶⁴ Furthermore, in a prospective, randomized study of 100 patients undergoing initial genito-urinary prosthetic implantation, of which 14 were AUS, post-prep cultures were positive in 8% of the chlorhexidine-alcohol group compared to 32% of the povidone-iodine group ($P < 0.01$). Notably, no urethral or genital skin complications occurred in either group.⁶⁶

Five-minute pre-operative, topical antimicrobial scrub is recommended. (*Grade of recommendation B*)

In a prospective cohort study of 100 consecutive AUS cases who all received povidone-iodine skin disinfection before incision, topical antimicrobial scrubbing with 4% chlorhexidine to the abdominal and perineal sites for 5 days pre-operatively was compared with normal patient hygiene (soap and water).⁵¹ The pre-operative topical antimicrobial scrub resulted in a fourfold reduction (OR 0.23, $P = 0.003$) in the pre-operative perineal colonization rate and an overall decrease of positive surgical site cultures.

Perineal versus Transcrotal incision. The perineal approach (PN) is preferred AUS cuff placement. (*Grade of recommendation C*)

AUS implantation can be performed through either a PN or TS approach. The former represents the traditional technique for AUS insertion as it offers the best exposure to the whole urethra for proximal bulbar urethral cuff placement. In a review of 63 TS and 63 PN AUS cases, 29% of TS and 56% of PN patients were dry ($P = 0.01$). Furthermore, 18% of TS cases required tandem cuff placement versus 3% of PN cases ($P = 0.06$).⁶⁷

In some select instances, the TS approach may represent a useful alternative to PN AUS cuff placement. (*Grade of recommendation D*)

Although, patients with conditions that preclude them from being placed in lithotomy—such as morbid obesity, spine or limb deformities, or neuro-motor conditions, among others—could theoretically be approached through a TS incision in supine position, the expert consensus panel recollected that the PN approach should be encouraged at all cost. Another group of patients in whom a TS incision might be preferred include certain re-do cases where severe scarring and fibrosis are expected in the perineal area and a more distal cuff placement is desired. Finally, patients with concurrent erectile dysfunction who opt for dual insertion of an AUS and a penile prosthesis (PP) may benefit from a single TS incision. In a series of 22 patients undergoing dual AUS/PP insertion through a TS incision, the overall revision rate was 14%, due to urethral erosion of the AUS in two patients and reservoir migration in one. All patients reported improved urinary leakage requiring one pad daily or less.⁶⁸ In a study by Wilson et al.⁶¹ of 30 patients undergoing an enhanced TS technique, no intra-operative complications were seen, with all subjects being socially continent (one pad or less). Furthermore, in a retrospective series of 83 high-risk patients with history of prostate radiation therapy and cryotherapy who underwent TS AUS placement, the mean number of pads/day decreased from 6.7 pre-operatively to 1.1 post-operatively. Overall, 83% of the patients (79% of the irradiated group and 85% of the non-irradiated group) used one or fewer pads per day after surgery.⁶⁹

Peri-urethral versus trans-corporal implantation. Urethral dissection should always be carried out sharply and under direct visualization, confirming urethra integrity by any preferred modality. (*Grade of recommendation D*)

The standard approach is peri-urethral. The TC approach may be considered under certain circumstances, such as patients presenting a history of urethroplasty, prior urethral erosion, evidence of extensive radiation effect on the urethra, spongiosal atrophy, compromised tissues, and those with small urethras, in men who do not wish to maintain erectile function. (*Grade of recommendation D*)

The presence of a PP or plan to get one in the future should also be considered. (*Grade of recommendation D*)

Anatomic and surgical considerations for peri-urethral dissection. In the bulbar urethra area, the urethra is eccentric, with the lumen biased toward the dorsal aspect. The corpus spongiosum is fused in this dorsal area to the corporal septum. Since dissection by the PN approach takes the dorsal aspect of the urethra as the apex of the dissection, it is most likely to be injured at this aspect. In addition, subtle injury in the area may be missed and could be more difficult to repair than one in a

lateral or ventral position. For these reasons, dissection should always be sharp and under direct view, as obscured vision and/or blunt dissection are much more likely to create injury. To rule out any subtle injuries, the urethra may be irrigated in a manner that will demonstrate injury, such as peri-catheter irrigation under pressure or occlusion proximal to the dissection.

Anatomic and surgical considerations for TC dissection. The element of the TC approach that makes it useful is the tunica albuginea (TA) flap incorporated under the cuff. This material is strong and not subject to much compression. The spongy tissue of the corpora cavernosa does not add to this flap, as it compresses easily and will lead to cuff oversizing. The TA does not lend itself to blunt dissection, and so dissection should be done sharply and as close to the TA surface as possible. To accommodate the cuff, the TA should be incised just over 2 cm long and the lateral edges should be closed to each other to prevent post-operative bleeding. Generally, the TC site should be distal to the corporal crus, to make closure of the TA easier. Even though the urethra is farther away from the dissection and is separated by the TA, it still should be isolated and carefully inspected to confirm its integrity. For TC cuff sizing, it is critical to not undersize the cuff to consider placing it $\frac{1}{2}$ cm larger than the measurement. This is particularly true for older men, as the rate of post-operative urinary retention is higher in these patients (32% vs. 8% in peri-urethral dissection).⁷⁰

Cuff sizing and choice. The choice of cuff size should be made by precise measurement, without indenting urethral circumference for all cuffs. (Grade of recommendation D)

If the measurement is between sizes, choose the larger size; avoid placing a cuff that is smaller than the measured urethral circumference. Measuring the urethra to ascertain proper cuff size is detailed in the operating manual for AUS placement: "The surgeon determines the proper size to be used in the patient by measuring the circumference of the tissue around the urethra or bladder neck."^{71,72}

The results with InhibiZone[®] antibiotic coating are not better than those without coating, and device costs are higher. (Grade of recommendation B)

InhibiZone[®] antibiotic coating has been developed for the cuff and the pump to reduce device infections. The results have not improved in terms of continence rates. Indeed, a retrospective study demonstrated no difference in infection rate in 426 consecutive patients divided equally into with and without InhibiZone[®] coating. Device cost was higher without any benefit noted.⁷³

Contrast versus saline solution. Prosthesis may be filled with either sterile saline or contrast filling solution. (Grade of recommendation D)

Either sterile saline or contrast filling solution may be used. Contrast filling solution allows radiographic visibility of the system for future reference to help with trouble-shooting device malfunction. However, some contrast materials have been thought to be hypertonic and viscous, posing a risk of poor fluid transmission in the device and fluid movement across the semi-permeable silicone reservoir membrane.²² No consistent data currently support this statement and, if contrast filling solution is used, the manufacturer's recommendations should be respected (AMS800 Urinary Control System Operating Room Manual 230025 Rev 09/09).

Pressure-regulating balloon (PRB). 61–70 cmH₂O PRBs should be used for most patients implanted with bulbar urethral cuff. (Grade of recommendation B)

Early analysis of patients undergoing AUS implantation with a bladder neck or bulbous urethral cuff compared the degree of continence to device removal rates and suggested that the optimal choice of balloon pressure was 61–70 cm H₂O.⁷⁴ These findings have stood the test of time and currently the 61–70 cm H₂O PRB is used in 94% of cases worldwide. The 71–80 cmH₂O PRB may be preferred in patients with a bladder neck cuff, at the surgeons' discretion.

PRB filling volume range with empty cuff should be 22–27 cc, depending on cuff size and number of cuffs (Grade of recommendation D)

The manufacturer recommends filling the PRB with 22 cc fluid while the cuff is empty, subsequently allowing it to fill with at least 20 cc of fluid remaining within the PRB—to maintain the desired pressure range. Larger cuff sizes may require more filling solution and, in selected cases, intra-operative cuff pressurization may be considered to help determine appropriate total system fluid volume (American Medical Systems: 2014 Operating Room Manual)

For optimal function, PRBs must be placed under the abdominal wall fascia and may be inserted into the retro-pubic space or into a space created between the abdominal musculature and the transversalis fascia, depending on patients characteristics and surgeon preference. (Grade of recommendation D)

PRBs should be placed into an intra-abdominal location. The most common position in the past was an extra-peritoneal site within the pelvis or retro-pubic area, accessed through the external inguinal ring or a lower abdominal incision. This technique remains in use, although the procedure may be more difficult in patients with scarring or bowel adhesions in the pelvic or retro-pubic space as may occur after robot-assisted laparoscopic prostatectomy or extensive pelvic surgery. In 2005, Wilson and Delk⁷⁵ described ectopic PRB placement in a space between the abdominal fascia and transversalis fascia by perforating cephalad through the external inguinal ring. Entry into the retro-pubic space was avoided in this method. Nineteen patients showed no difference in function or urethral atrophy, although PRBs migrated out of position in two of them. When necessary, PRBs may also be placed into this ectopic space directly through the rectus fascia via the small lower abdominal incision made for pump insertion. According to a recently described technique, the external ring is perforated cephalad and parallel to the transversalis fascia through an upper scrotal incision, with a long lung-grasping clamp to place the PRB into a high abdominal location between the rectus muscle and the transversalis fascia. The maneuver was associated with a low incidence of migration and palpability.⁷⁶ PRBs implanted in this manner demonstrated similar rates of continence, cuff erosion and surgical revision compared to those housed in the retro-pubic space.⁷⁷

Pump implantation. The pump should be placed in the dependent portion of the scrotum, anterior to the testicle, to ensure that patients can access it post-operatively. (Grade of recommendation D)

To ensure that patients can easily access and manipulate the AUS pump post-operatively, it should be placed anterior to the testicle in the dependent portion of a hemi-scrotum. Also,

patients should be encouraged to pull down on the pump several times a day during the immediate healing period to prevent pump cephalad migration. Typically, the pump is placed in the hemi-scrotum on the ipsilateral side as the patients' dominant hand. However, patients can learn to use a pump on the contralateral side without much difficulty.

Connections in primary implants and revision. The Quick Connector System should be incorporated in all AUS placement. (Grade of recommendation D)

Although no data are currently available in the literature, all experts agree that the Quick Connector System, specially developed for the AMS800™ device, should be systematically included for primary implantation as well as revision procedures.

In case of revision, the tubing may be completely replaced to ensure effectiveness of the Quick Connector System. (Grade of recommendation D)

It is vital to note that AMS guarantees fixation performance of Quick connect Sutureless Window Connectors only in the presence of new components. In other words, according to AMS, in case of a revision procedure, previously implanted component tubing should be removed and replaced to ensure correct and safe connections.

Intra-operative assessment of efficacy. Urethral injury should be ruled out and proper functioning should be confirmed by device cycling. (Grade of recommendation D)

Once the entire device is implanted, it is important to rule out urethral injury with a preferred method of choice. This can be done with retrograde instillation of saline, with or without dye (methylene blue), simultaneously with external visualization of the urethra. Intra-urethral indigo carmine solution after urethral mobilization in men undergoing AUS insertion can identify urethral injury but does not prevent early cuff erosion.⁷⁸ Direct endoscopic vision with cysto-urethroscopy can also be useful for both standard and high-risk urethras (i.e., after radiation or urethroplasty). The literature does not support one method over another.

The device should be cycled several times under direct visualization to ensure adequate function of the hydraulic mechanism. (Grade of recommendation D)

The device should then be inactivated with a small amount of fluid in the pump chamber to enable subsequent activation.

In addition intra-operative assessment can determine efficacy or adequate cuff sizing. Cuff fit can be evaluated by visual or endoscopic appearance. A cuff that strangulates the urethra or that fits too loosely should be changed. Urethroscopy can also confirm good cuff sizing.²³ AUS efficacy can be tested by retrograde perfusion sphincterometry. This method first examines the bulbar urethra intra-operatively with a flexible cystoscope and then assesses reservoir pressure by retrograde fluid irrigation at the distal third of the urethra. It has detected urethral injury in 8% of men and device malfunction in 20% of patients.⁷⁹

Closure and dressing. Closure should be done multi-layered with absorbable sutures after copious irrigation. (Grade of recommendation D)

All surgical sites should be irrigated copiously with sterile saline with or without antibiotic solution. All surgical sites

should be closed in multiple layers with absorbable sutures. Abdominal incision site fascia should be closed with long-duration, absorbable sutures, and the skin closed with either clips or absorbable sub-cuticular suture. Layers of perineal surgical sites to be closed are the bulbo-spongiosus muscle, the dartos layer and the skin. Care should be taken to avoid contact between needles and any AUS component.

Post-Operative Care

Immediate post-operative care. Catheters should be less than 14 French and should be removed after a brief period (usually overnight). (Grade of recommendation D)

Post-operative length of stay will depend on the time of catheter removal. Indwelling urethral Foley catheters of 14 French or less are advisable to decrease any pressure on the surrounding bulbar urethra at the cuff site. No data on the ideal timing of catheter removal, are available, but same-day removal may increase the risk of urinary retention due to pain or inflammation. It is best to remove the catheter after a brief period (usually overnight) if the surgery is uneventful. Prolonged catheterization (over 48 hr) has been associated with increased risk of cuff erosion.⁸⁰

Discharge instructions could include no lifting, bending, or any activities that would increase Valsalva pressure. Patients are advised to pull down on the pump when the inflammation and pain decrease—to keep it as low as possible in the scrotum.

Post-operative prescriptions. Post-operative prescriptions should consist of oral analgesia and stool softener, if indicated by patient history. (Grade of recommendation D)

No specific evidence is guiding the selection of post-operative prescriptions in AUS patients. Common practice dictates that patients be supplied with medication for analgesia appropriate for the treatment of pain related to surgical dissection and incision. The selection of particular agent is influenced by patient allergies, physician preference and prior patient response to analgesics. Utilization of oral opioids necessitates prophylaxis against constipation.⁸¹ Therefore, a stool-softening agent may be prescribed, especially for patient with pre-existing bowel evacuation problems.

No evidence supports the standard administration of post-operative antibiotics. (Grade of recommendation B)

The absence of a reference to antibiotics in the present recommendations is based on lack of evidence supporting a course of routine oral post-operative antibiotics, especially in the absence of catheter placement and/or patient risk factors.

No randomized data reflect the evaluation of prolonged antibiotic courses in genito-urinary prosthesis implantations. Post-operative oral antibiotic courses (quinolones, cephalosporin, or trimethoprim-sulfamethoxazole) of varying lengths are reported inconsistently in AUS series.^{16,73,82,83} However, high quality literature, assessing antimicrobial prophylaxis for mesh herniorrhaphy, joint prosthetics and spinal surgery with instrumentation, reveals no benefit from extending antibiotic therapy for more than 24 hr post-operatively.⁸⁴

Evaluation of the organisms associated with AUS infection has demonstrated that gram-positive cocci, primarily *Staphylococcus aureus*, are the most common causative bacteria.⁸⁵ Therefore, any extended therapy should be focused on this group of organisms.

Patients should be advised to limit physical activity and lifting of more than 6 kg during the 6-week post-operative period. (*Grade of recommendation D*)

Even if there are currently no available data on physical activity and lifting limitations after AUS implantation, the expert consensus panel chooses to give an order of magnitude of such constraints. It is important to note that the present statement is not supported by any strong evidence, but is only issued as expert opinion. Extrapolating precautions usually taken in abdominal surgery and experts' common practice in terms of physical activity, we state that patients should be advised to limit their physical activity and lifting over 6 kg during the 6-week post-operative period. This will probably apply all the more to women, who usually undergo an abdominal wall incision at the time of AUS implantation.

Time of activation. Virgin AUS should be activated at 4–6 weeks post-implantation. (*Grade of recommendation D*)

The post-operative deactivation period is dictated by both common practice and patient comfort. Scrotal swelling and discomfort must resolve sufficiently to allow normal periodic cycling throughout the day. Review of AUS series reported median activation time of 6 weeks.^{25,52,72,86–88} Increasing deactivation time, based on prostate cancer treatment characteristics such as radiation, has been reported.⁸⁹ There is no definitive evidence that extension of deactivation beyond 6 weeks is beneficial.

Activation times after removal/replacement, device revisions, and individual component replacement may be adjusted on the basis of clinical situation and patient comfort. (*Grade of recommendation D*)

AUS surgeries after original device placement are heterogeneous. The extent and invasiveness of surgeries depend on the need for dissection of new component sites and the number of components manipulated or replaced. Hardly any references suggest adjustment of the deactivation period, depending on technical difficulty of the operative procedure and the resultant scrotal swelling and edema.⁹⁰ Revisions that do not involve dissection for a new cuff location and/or do not disturb the pump are unlikely to cause any discomfort. It is reasonable and consistent with expert opinion to apply a graded approach to determining the length of the deactivation period.

Postoperative teaching. Patients must demonstrate ability to properly cycle AUSs. (*Grade of recommendation D*)

At the time of activation, patients should be observed working the AUS pump. Healthcare provider should confirm that patients successfully depress the pump sufficiently to transfer fluid from the cuff, resulting in a normal voiding duration.

Patients should be fore-warned by healthcare professionals in the event that catheterization is planned. They should avoid perineal pressure. They should be instructed to wear a *MediAlert* type of bracelet. (*Grade of recommendation D*)

The correlation between indwelling urethral catheterization and the potential for urethral injury at the AUS cuff site is well known.⁹¹ Patients should be informed about the risks of device damage—immediate and long-term—when catheterization is necessary. Devices should be deactivated by either patients or experienced healthcare providers prior to

catheter placement (12 or 14 French). Even catheters placed properly for short periods may be detrimental to long-term device survival. Seideman et al.⁸⁰ demonstrated increased risk of erosion in patients who were catheterized for more than 48 hr at any time after AUS placement. Therefore, patients requiring longer catheterization should undergo urological consultation to ascertain the best strategy for LUT management.

Intermittent catheterization is source of repeated urethral traumas.⁹² However, no data analyzing urethral erosion in the AUS context are currently available. Actually, most of patients undergoing intermittent catheterization are neurogenic so that the cuff is usually placed around the bladder neck. Such specificity has been reported to limit the risk of urethral erosion in the context of long-term intermittent catheterization.⁹³ Since intermittent catheterization is considered the best option for bladder drainage in this specific population, the expert consensus panel suggests no contraindication in the presence of an AUS, provided the device is correctly deactivated previously.

The effects of activities requiring constant or intermittent perineal pressure on AUS function and longevity have not been analyzed in the literature. Logic dictates that the AUS cuff and surrounding urethra should be protected from traumatic forces. Therefore, patients are counseled to avoid activities which require straddling—horseback riding, motorcycle riding, and bicycle riding. The availability of bicycle seats with alternate configurations—“split or donut”—makes this activity feasible with the appropriate equipment.

To reduce the likelihood of inadvertent traumatic catheterization, a notification bracelet is indicated based on the negative impact of urethral catheterization without appropriate deactivation in unconscious or unskilled patients. Wording on the bracelet should inform about device presence and suggest urological consultation prior to any urethral instrumentation.

Mid- and long-term follow-up. Physical long-term follow-up should be ensured between 3 and 6 months post-operatively and periodically thereafter. (*Grade of recommendation D*)

Subsequently, yearly follow-up may be undertaken in person or by questionnaire with mandatory evaluation of symptoms consistent with device malfunction, infection and/or erosion. (*Grade of recommendation D*)

Following the deactivation period, the pattern of follow-up visits is modeled after clinical practice for many surgical procedures. However, prosthetic device implantation with a high revision rate and finite lifespan obligates long-term patient interaction. A review of AUS series from 1985 to 2015 found that the minority reported a follow-up strategy; the time points most commonly mentioned were 3 months and 1 year, followed closely by 6 months post-operatively. To identify early complications requiring revision within the first several months of use, 3- and 6-month visits are the most critical with subsequent frequency being adjusted on the basis of individual clinical circumstances. Ideally, standard follow-up should be conducted yearly—physically or by completion of a validated urinary-specific questionnaire.

Patients must be encouraged to update the implanting surgeon immediately regarding any changes in continence/voiding symptoms, UTI, new onset hematuria and/or scrotal discomfort, to establish whether physical examination ± cystourethroscopy are necessary. Prompt identification of infection and/or erosion facilitates intervention before any further local or systemic consequences occur.

Trouble Shooting

Incomplete continence and partially functioning AUSs. Patients who complain of leakage problems after AUS placement may have technical issues with the device, another urodynamic factor or a combination of the two. (Grade of recommendation D)

Several Situations Can Cause Issues of Leakage, or Perceived Leakage, Even With a Fully Functioning Successful AUS

Confidence pad. A large proportion of men persist in wearing containment products, even when they actually do not experience leakage, and change their pad only once daily. "Confidence pads" reflect the fact that such men may have experienced many years of leakage impacting their ordinary social and occupational functions, with persistent psychological results. It is the patient's choice, with no intervention indicated.

Strenuous physical exertion. The ability of AUSs to resist changes in intra-abdominal pressure is set by the PRB and is less than that of the native sphincter. Hence, it will be exceeded during strenuous physical exertion.

Post-micturition dribble. Leakage after voiding is common. It can happen if AUSs are not given enough time to fully close after voiding, that is, if the patient dresses too soon after emptying the cuff, such that it does not have time to refill completely.

Elevated storage pressures. Storage phase urodynamic factors present pre-operatively, notably, DO or poor bladder compliance, may lead to leakage. In cases where detrusor pressure rises to the same level as the AUS compression, incontinence will follow.

BOO and overflow. Chronic urinary retention can likewise bring detrusor pressure to the same level as AUS compression, so that incontinence will follow. Pre-operative UDS in these patients may show partial BOO or detrusor under-activity with

voiding. Alternatively, BOO may be a result of problems during AUS placement (e.g., an undersized cuff or urethral distortion) or secondary development of urethral stricture.

Pseudo-incontinence. The sensation of leakage by patients without any objective incontinence may be termed "pseudo-incontinence." It can reflect filling of the proximal urethra above the AUS, and likely represents stimulation of urethral receptors.

The Technical Aspects Potentially Affecting the Normal Function of the AUS Device May Include

Reduction in the system pressure. This parameter could reflect fluid loss from the system, or insertion of insufficient fluid at the time of AUS placement. Fluid loss may result from failure of a joint between AUS components, stress-fatigue of tubing, or a penetrating event, for example, AUS contact with a needle.

Overly large AUS cuff. This situation could occur if the urethra is measured inaccurately at the time of placement, or if urethra caliber is reduced (sub-cuff urethral atrophy) with long-term compression by the cuff.

Distortion and/or air bubbles. Fluid flow may be impeded in AUS tubing by distortion or air bubbles. They may also result if the inactivation button fails to release fully.

Improper engagement of cuff tab. A rare finding—if the tab is not seated properly, the cuff will not work effectively. This condition may be encountered during revision surgery, in patients where the AUS appears to be functioning but the symptoms are not controlled.

Assessment of men with unsatisfactory outcomes after AUS requires a logical approach to determine if AUS malfunction, urodynamic factors or other influences occur. (Grade of recommendation D)

Considerations during history-taking and examination are detailed in Table I. Basic investigations are chosen according to

TABLE I. Management of Persistent Incontinence or Partially Functioning AUS

	Potential findings	Treatment
History and examination	Urgency urinary incontinence	Behavioral and medical therapy
	Sensation of incomplete emptying	Further investigation
	Sensation without leakage	Explanation and advice
	Post-micturition dribble	Explanation
		Gentle manual urethral compression
	Distended bladder	Further investigation
		Catheterization with AUS inactivated (ISC)
		Further investigation
	Malfunction of pump chamber	
	Malfunction of inactivation button	
Flow rate and bladder scan	Lack of confidence	Reassurance
	Physically or mentally unable to use AUS	Explantation
		Inactivation
		Containment
	Review urodynamics done prior to AUS	Further investigation
	Abnormal pattern of flow	Further investigation
	Post void residual	Catheterization with AUS inactivated (ISC)
	Empty reservoir	Revision
	Empty or under-filled reservoir, cuff or pump	Revision
	Air bubbles	
Pelvic ultrasound	Cuff erosion	See relevant section
Abdomino-perineal X-ray ^a	Abnormal urethral pressure profile, storage or voiding	Manage according to findings
Cysto-urethroscopy	Cuff tab not engaged	Engage tab
Urodynamics	Urethral atrophy	Revision
Further findings in surgery		Additional cuff

ISC, intermittent self-catheterization.

^aFor contrast-filled AUS.

clinical features, and include flow rate and PVR measurement, X-ray imaging (where AUSs are primed with contrast mixture), ultrasound and UDS. Urethroscopy may be warranted if there is any indication of cuff breach into the urethra. Improper cuff tab engagement may be suspected if the device, appears to be functioning perfectly, but has never brought clinical benefit from the first activation after placement. Urethral atrophy may be suspected if a device, which has been functioning for some time after placement, becomes increasingly ineffective.

Sub-cuff urethral atrophy. Sub-cuff urethral atrophy is defined as progressive loss of initial continence after AUS implantation in the absence of erosion, mechanical malfunction or leak and/or bladder-related causes of worsening urinary continence.

In AUS patients presenting with recurrent or gradual worsening of incontinence, sub-cuff urethral atrophy should be considered as diagnosis of exclusion, after dismissing erosion on cysto-urethroscopy and mechanical failure by other modalities. (Grade of recommendation D)

Very few publications have dealt with the problem of recurrent incontinence after AUS placement. Articles covering AUS trouble-shooting provide some information, but the true incidence of sub-cuff urethral atrophy is impossible to determine on the basis of suboptimal and sparse retrospective data complicated by no acceptable and uniform definition with standardized evaluation.^{94,95}

Treatment should first take the most conservative revision approach, followed by procedures for cuff revision requiring complex surgery or additional hardware. (Grade of recommendation D)

In most cases, the preferred first approach is cuff downsizing or replacement at a different site, more proximal whenever possible.^{26,96} Other modalities such as tandem cuffs,^{97–100} TC cuffs^{101–103} or higher PRB pressures, can be considered. The introduction of smaller 3.5-cm cuff has allowed smaller urethral circumferences to be measured and treated appropriately while recognizing increased risk of cuff erosion in patients with a history of radiation therapy.^{53,57}

AUS infection. Infection occurs in <5% of AUS cases,¹⁰⁴ usually manifested by inflammatory changes over the scrotal pump. The most common offending organisms in AUS infections are gram-positive skin flora: Methicillin-resistant *S. aureus* and *Staphylococcus epidermidis* are being cultured with increasing frequency. Gram-negative organisms are uncommon, and the presence of anaerobic and fungal organisms is unknown.⁸⁵

If AUS infection is suspected, cysto-urethroscopy should be undertaken to evaluate the urethra for cuff erosion. In gross or persistent infections, the entire device should be explanted as soon as it is clinically safe. (Grade of recommendation D)

Urethral cuff erosion is a common precipitating cause of AUS infection. Thus, prompt cysto-urethroscopy is recommended to evaluate urethral integrity when infection is suspected. In the absence of cuff erosion, a trial of broad-spectrum antibiotics may be attempted for mild cases.

In infection, device removal and delayed re-implantation are preferred over immediate salvage re-implantation. (Grade of recommendation D)

Patients with advanced or persistent infection should usually be treated by complete device removal, followed by re-

implantation at least 3 months later when the infection is well-controlled and the clinical setting is optimized. Immediate salvage re-implantation of infected, non-eroded AUS after antiseptic irrigation has been reported,¹⁰⁵ but is not commonplace practice.²²

Urethral cuff erosion. At urethral cuff exposure or erosion, the decision to remove the cuff exclusively or the device entirely will mainly depend on time since AUS implantation. (Grade of recommendation D)

Urethral cuff exposure occurring during the immediate peri-operative period (less than 6 weeks) should be treated with cuff removal and preservation of the remaining AUS portions in the absence of any evidence of infection.¹⁰⁶ It is likely the result of unrecognized iatrogenic urethral injury or urethral thinning.^{80,107} A limited amount of evidence suggests any role for salvage therapy in these cases.¹⁰⁸

Urethral cuff erosions occurring more than 3–5 years after initial implantation may require complete AUS removal and replacement of all its components, depending on mechanical functioning of the device.

The decision to perform concomitant urethroplasty should be based on the extent of urethral loss at the time of cuff explantation. (Grade of recommendation D)

Urethroplasty at the time of device explantation may be required to ensure stricture-free healing in cases of severe erosion with circumferential urethral loss.^{109,110} When erosion involves only a sector of the urethral wall, the cuff can be simply explanted and the urethra stented with a 14–16 French catheter for 2–4 weeks. Some data suggest that immediate urethral repair during explantation prevents stricture formation after AUS cuff erosion.¹¹¹

Eroded cuffs should be replaced at different urethral locations or even through a TC approach, depending on local conditions. (Grade of recommendation D)

Eroded cuffs should be replaced at different urethral locations, if feasible.²⁸ If not, surgeons should consider TC placement of new cuffs.^{102,112} In cases of AUS removal because of cuff erosion, surgeons should re-evaluate patients in 3 months to ensure that the urethra has healed appropriately prior to re-implantation. This evaluation includes cystoscopy and, in select cases, retrograde urethrography.

Mechanical failure. Mechanical AUS failure is common, increases over time²⁵ and is characterized by sudden UI without signs and symptoms of cuff erosion.

Whole system replacement is generally preferred at the time of AUS replacement of a malfunctioning device. (Grade of recommendation D)

In select cases where a component can be identified by either intra-operative demonstration of a leak¹¹³ or by ohm-meter¹¹⁴ and the original AUS was placed recently, single component replacement may be considered.

Definitive diagnosis of mechanical AUS failure is demonstrated by decreased fluid in the system, either by intra-operative aspiration or pre-operative radiologic evidence of diminished fluid in the PRB. (Grade of recommendation D)

Cysto-urethroscopy alone can rule out cuff erosion but cannot be the only modality to make the diagnosis of mechanical failure.

Outcomes

How do we define success?. Reported outcomes post-AUS are variable and need to become standardized. (*Grade of recommendation D*)

Efficacy outcomes should include but should not be limited to: the number of patients with no pad, occasional or regular pad, pads/shields/diapers type used, a validated quality of life measurement and, of course, device survival.^{115,116}

Special Populations

TC AUS in the setting of an inflated penile prosthesis (IPP). While simultaneous AUS/IPP implantation and the TC AUS procedure have been described separately in the literature,^{68,101,117–119} there are no data on simultaneous IPP implantation or staged in regard to TC AUS cuff placement. Therefore, opinions on this subject are based on personal experience rather than studies.

IPP placement after TC AUS cuff procedures should be considered a high risk. (*Grade of recommendation D*)

In experienced surgical hands, however, these procedures can be accomplished either in a staged fashion or simultaneously.¹²⁰

Because of increased IPP placement risk in patients with TC cuff, the procedure should be done in specialized, high-volume centers. (*Grade of recommendation D*)

It should be noted that TC AUS can have a potentially negative impact on erectile dysfunction. (*Grade of recommendation D*)

However, there are no published data on the frequency and degree of impact on erectile function with the TC technique. Regardless, PPI patients with adequate erectile function prior to planned TC cuff placement need to be warned about a potentially negative outcome. Also, implanting surgeons must sufficiently justify the added negative risk versus benefit of the TC procedure.

AUS and neurogenic incontinence. AUSs can successfully manage UI in neurogenic bladder patients. (*Grade of recommendation B*)

In this specific population, implantation classically requires retro-pubic dissection to place the cuff around the prostate (in men) or bladder neck (in women), making surgery quite a bit more challenging. However, AUSs have been shown to provide acceptable long-term outcomes in both male¹²¹ and female neurogenic patients.¹²² They are advocated by many authors as primary or secondary treatment of patients who have failed other forms of bladder outlet surgery.^{123,124}

AUS erosion is frequent in neurogenic patients, and all effort should be made to prevent its occurrence. (*Grade of recommendation B*)

AUS erosion is the major cause of AUS removal in contemporary neurogenic bladder series, with a rate reported to go from 6% to 31%.^{125,126} Cuff placement around the bulbar urethra or around the bowel to create a neobladder has been found to heighten the likelihood of erosion.^{125,126} Consequently, AUSs should be implanted systematically in a peri-prostatic position, and simultaneous augmentation cystoplasty should be considered as a risk factor for AUS survival. Furthermore, intermittent catheterization could be associated with high-level erosion due to repeated urethral traumas.^{127,128}

The expert consensus panel insists on the importance of patient teaching of the catheterization technique and the AUS deactivation procedure to prevent AUS erosion in this specific population.

AUSs should be placed with caution in this population because of a higher numerical complication rate versus post-prostatectomy patients. (*Grade of recommendation B*)

AUS implantation is coupled with specific complications in neurogenic patients, mainly because of retro-pubic and bladder neck dissections, which have been reported to be occasionally responsible for bladder neck, urethral and rectal perforations.^{127,129} AUS infection leading to sphincter removal, has been found to be more frequent—as high as 8%¹³⁰—among neurogenic patients than what was usually seen in non-neurogenic patients. It is noteworthy that the AUS infection rate does not appear to increase in patients who catheterize compared to those who void spontaneously or who empty their bladders with the Credé maneuver.¹³¹

Alternative therapies, including fascial slings, bladder neck reconstruction, adjustable continence therapy, and injection of urethral bulking agents, are available. (*Grade of recommendation D*)

Fascial slings and bladder neck reconstruction were considered gold standard procedures in this population until a few years ago, and are still an option in some cases. However, their invasiveness often led surgeons to choose far less tissue-damaging procedures, including ACT and injection of urethral bulking agents. While no results are currently available from RCTs comparing these techniques head to head, ACT and urethral bulking agent injections seem to be less effective.^{132,133}

Long-term follow-up with bladder and upper urinary tract monitoring is essential. (*Grade of recommendation D*)

Patients who receive AUSs must undergo long-term urological follow-up with UDS monitoring and upper tract imaging to detect upper urinary tract deterioration. Indeed, the proportion of AUS recipients with neurogenic bladder who ultimately require augmentation cystoplasty have been reported to range from 4% to 42%.^{126,127,134}

AUS and catheter placement. Placement of indwelling urethral catheters in patients with AUSs is the most common cause of erosion. (*Grade of recommendation B*)

Despite the multitude of reports clearly outlining erosion risk factors, Sedeiman et al.⁸⁰ were the first to identify that prolonged indwelling catheterization represents an independent factor of AUS cuff erosion. Their analysis included 258 patients, of whom 200 met the inclusion criteria. AUS cuff erosions from all causes were seen in 24 (12%) at a mean of 16.9 months after placement. Urethral catheterization was noted in 44 (22%) of 200 men, and 17 (39%) of these 44 subsequently developed erosions ($P < 0.001$, hazard ratio 3.39). The most typical indications of catheter placement in this series were for non-urologic surgery or urinary retention. Because urethral catheterization is common in hospitalized patients (25%), all healthcare providers should be aware of patients who may have AUSs in place.^{91,135} In these situations, AUS cuff compression with catheter placement causes direct trauma to the urethra, and if the system is not properly deactivated in the open position, it may lead to compression with resultant ischemia and erosion. Urological consultation is mandatory in all such cases where catheterization is required in patients with AUSs in place.⁹¹

When catheters are absolutely required in AUS patients, the device must be inactivated in the open position, and the smallest size urethral catheter should be used for the shortest time period (less than 48 hr). (*Grade of recommendation D*)

While acute urinary retention immediately after AUS placement is rare, it may be more frequent with TC and 3.5-cm cuffs.⁷⁰ This parameter should be managed in the immediate post-operative period by bladder drainage with a small (French) catheter for a very short time (24–48 hr). Cuff deactivation in the open position must be confirmed before catheterization, as a common cause of retention in this group is inadvertent device activation in the post-operative recovery period. Placement of a supra-pubic cystostomy tube is recommended when urinary retention extends beyond 48 hr and is required when the period reaches 7 days, to reduce the risk of urethral erosion. Radiographic guidance for supra-pubic tube placement with ultrasound, CT scan or fluoroscopy is proposed to prevent damage to the sphincter. Late-onset urinary retention mandates endoscopic evaluation to rule out proximal urethral obstruction and cuff erosion.

When fluid monitoring in obtunded patients is required, the device should be deactivated and an externally secured collection method, such as a condom catheter, should be attempted. (*Grade of recommendation D*)

In many typical in-patient situations requiring bladder drainage, patients can often be simply managed by device deactivation allowing urine to flow out via resultant incontinence. Accurate fluid monitoring can be achieved by weighing pads that the patient leaks into or by the placement of external collection devices, such as condom catheters. In rare situations when catheterization is absolutely necessary, it is imperative to place the smallest catheter possible for the shortest time period. Urological consultation is mandatory in these situations. The AUS must be deactivated in the open position and a small French Foley catheter placed.

In cases that require prolonged drainage (>48 hr), a supra-pubic tube should be considered, with imaging guidance. (*Grade of recommendation D*)

AUS and women. AUS is indicated in cases of pure SUI or mixed UI in female patients if ISD is present and is the main reason for SUI. (*Grade of recommendation D*)

Pure ISD without any urethral hypermobility is a rare condition seen in neurological conditions, after multiple peri-urethral surgeries and pelvic traumas. Outside these specific conditions, where AUSs can be offered after discussion with patients and considering surgeons' experience, the use of AUS to treat severe SUI in women is not common.^{136,137}

The mechanism of AUS action is the main reason for advocating its indication in some women: its ability to close the bladder neck, procuring passive continence, and its complete opening during micturition, make it probably more "physiologic" than some slings.

AUSs have never been compared in this population with any technique, especially slings. In non-neurogenic women, AUSs are a salvage technique in bothered patients after mid-urethral sling failure in the absence of urethral mobility. (*Grade of recommendation D*)

Large prospective cohorts or retrospective studies of AUSs in women have shown benefits and risks of the device.^{122,138–145} Standard treatments vary from one country to another, depending on surgeons' training and experience. In women

with severe incontinence, since pubo-vaginal fascial slings are considered by many surgeons to be an alternative to AUS, a comparative study of the two techniques would be appropriate.^{146,147}

AUSs in women are contra-indicated after pelvic radiotherapy. (*Grade of recommendation D*)

Considering that silicone prostheses are implanted through extensive dissection, it has been shown that previous radiation increases infection and/or erosion risks. It is an expert opinion that past pelvic radiation therapy should be considered a contraindication for AUS implantation.¹⁴³

The retro-pubic approach is recommended over the vaginal approach because of a lower infection rate. (*Grade of recommendation B*)

The vaginal route has been abandoned because of its high risk of infection and erosion. The recommended technique is a retro-pubic approach of the bladder neck without opening of the vagina.¹⁴⁵

Laparoscopic and robotic AUS implantation techniques have been proposed recently.^{148–152} The few data published have to be analyzed carefully, considering a higher rate of bladder and/or vaginal injury leading to abortion of AUS implantation or the occurrence of short-term erosion. These new technical approaches have to be tested by teams routinely implanting AUSs in females through open surgery.

Future of AUS

What is the AUS of our dreams? The present AUS version (AMS800™) has some limitations that can only be overridden by the emergence of a new AUS class. Indeed, the current AMS800™ device was marketed since 1983 and has never submitted to major improvements since then. A total of nine hydro-mechanical or purely mechanical AUSs have been reportedly developed at the time of our literature review.^{153–161} Three of them have already been implanted and studied in humans,^{153,157,159} but none has yet been directly compared to the AMS800™. They all have limitations, and further enhancements will undoubtedly be needed to finally achieve a really innovative device.^{162,163} In an attempt to guide future research, we have listed the characteristics that such a device would require.

The "ideal" AUS should be easily manipulated and inactivated.^{153,162} (*Grade of recommendation D*)

It should be easy to manipulate by patients and caregivers. Lack of manual dexterity is one of the main limitations to implantations or to continue with already-implanted AUSs.^{137,164} A device, which could be easily manipulated, would allow implantation in less skillful patients who currently cannot benefit from the AMS800™. This could be accomplished by remotely controlled AUSs, as proposed recently.^{155,156,160,161,165} Furthermore, easy AUS deactivation could also improve efficacy and safety. Continent patients in the lying position could transiently deflate the cuff during bedtime. This would limit continuous high-pressure urethral compression, in theory reducing the risk of urethral erosion and atrophy.^{160,166,167}

The "ideal" AUS should possibly modify cuff pressure after implantation.^{153,154,160,162,163} (*Grade of recommendation D*)

Persistent SUI is a relatively frequent complication (1.4–2%) of AUS implantation.^{26,72} In some cases, increasing cuff

pressure represents the solution. At present, re-operation to replace the cuff or PRB is the only option.^{96,101,168} Adjusting occlusive cuff pressure remotely according to continence status could be an interesting option and could presumably lower failure and re-intervention rates.

The “ideal” AUS should be able to adapt occlusive cuff pressure in a real-time manner.^{153,154,162,163} (*Grade of recommendation D*)

Pressure exerted on the bladder and urinary sphincter is highly variable, depending on abdominal pressure (physical exercise, coughing, laughing, etc.).¹⁶⁹ A device able to adapt occlusive cuff pressure to abdominal pressure in a real-time manner would mimic normal physiology. It would allow the reduction of baseline occlusive cuff pressure without impacting urinary continence. Such precautions will also theoretically decrease the risk of urethral erosion and atrophy.^{160,166,167}

The “ideal” AUS should have a simple and robust design.^{153,160} (*Grade of recommendation D*)

Mechanical dysfunctions have been reported to be frequent (7.6–21%) and responsible for a high re-intervention rate with significantly decreased quality of life during AMS800™ lifespan.¹⁷⁰ The hydraulic design concept and the three-piece device involving multiple connections have been implicated in a significant portion of mechanical dysfunctions associated with the AMS800™.¹⁷¹ The next AUS generation should definitely integrate more robust components and be designed as a one-piece, pre-filled device, limiting the number of connections or based on a non-hydraulic concept.

The “ideal” AUS should be safely implanted via a minimally invasive procedure.^{153,158,172} (*Grade of recommendation D*)

In all fields of surgery, minimally invasive procedures tend to become the new standard of care. Minimally invasive approaches have also recently been proposed for AMS800™ implantation and/or revision, particularly in neurogenic patients and women.^{93,148–152,173}

The “ideal” AUS should be as cost effective as possible.^{162,172} (*Grade of recommendation D*)

The AMS800™ is a costly device.¹⁶⁹ At present, when health-related expenditures are becoming a social priority, a novel AUS would be better accepted by healthcare systems if it was accompanied by reduced costs. This should be taken into account when designing new AUSs, regarding the production process as well as all costs associated with the implantation procedure and follow-up specifications.

CONCLUSION

The present guidelines are issued from brainstorming by 19 urological surgeons, all considered expert in the use of the AMS800™. The most recent and relevant data available in the literature as well as expert opinions were taken into account to reach a consensus on each of the presented statements. These recommendations will undoubtedly help urologists in their daily practice with the AMS800™.

ACKNOWLEDGMENTS

AMS (American Medical System Holdings Inc., Minnetonka, MN, USA) and ICS (International Continence Society, Bristol, UK).

REFERENCES

- Kadono Y, Ueno S, Iwamoto D, et al. Chronological urodynamic evaluation of changing bladder and urethral functions after robot-assisted radical prostatectomy. *Urology* 2015;85:1441–7.
- Newman DK, Guzzo T, Lee D, et al. An evidence-based strategy for the conservative management of the male patient with incontinence. *Curr Opin Urol* 2014;24:553–9.
- Wolski Z, Tworokiewicz M, Szabela-Polak A. Psychological aspect of qualification to implant an artificial urethral sphincter AMS 800. *Cent European J Urol* 2012;65:21–3.
- Wolin KY, Luly J, Sutcliffe S, et al. Risk of urinary incontinence following prostatectomy: The role of physical activity and obesity. *J Urol* 2010;183: 629–33.
- Galli S, Simonato A, Bozzola A, et al. Oncologic outcome and continence recovery after laparoscopic radical prostatectomy: 3 years' follow-up in a “second generation center”. *Eur Urol* 2006;49:859–65.
- Colombo R, Naspro R, Salonia A, et al. Radical prostatectomy after previous prostate surgery: Clinical and functional outcomes. *J Urol* 2006;176:2459–63; discussion 2463.
- Lepor H, Kaci L. The impact of open radical retropubic prostatectomy on continence and lower urinary tract symptoms: A prospective assessment using validated self-administered outcome instruments. *J Urol* 2004;171: 1216–9.
- Smither AR, Guralnick ML, Davis NB, et al. Quantifying the natural history of post-radical prostatectomy incontinence using objective pad test data. *BMC Urol* 2007;7:2.
- Goluboff ET, Saidi JA, Mazer S, et al. Urinary continence after radical prostatectomy: The Columbia experience. *J Urol* 1998;159:1276–80.
- Bauer RM, Gozzi C, Hübner W, et al. Contemporary management of postprostatectomy incontinence. *Eur Urol* 2011;59:985–96.
- Abrams P, Andersson KE, Birder L, et al. Fourth International Consultation on Incontinence Recommendations of the International Scientific Committee: Evaluation and treatment of urinary incontinence, pelvic organ prolapse, and fecal incontinence. *Neurourol Urodyn* 2010;29:213–40.
- Dmochowski RR, Blaivas JM, Gormley EA, et al. Update of AUA guideline on the surgical management of female stress urinary incontinence. *J Urol* 2010;183:1906–14.
- Ficazzola MA, Nitti VW. The etiology of post-radical prostatectomy incontinence and correlation of symptoms with urodynamic findings. *J Urol* 1998;160:1317–20.
- Pérez LM, Webster GD. Successful outcome of artificial urinary sphincters in men with post-prostatectomy urinary incontinence despite adverse implantation features. *J Urol* 1992;148:1166–70.
- Thiel DD, Young PR, Broderick GA, et al. Do clinical or urodynamic parameters predict artificial urinary sphincter outcome in post-radical prostatectomy incontinence? *Urology* 2007;69:315–9.
- Trigo Rocha F, Gomes CM, Mitre AI, et al. A prospective study evaluating the efficacy of the artificial sphincter AMS 800 for the treatment of postradical prostatectomy urinary incontinence and the correlation between preoperative urodynamic and surgical outcomes. *Urology* 2008; 71:85–9.
- Lai HH, Hsu EI, Boone TB. Urodynamic testing in evaluation of postradical prostatectomy incontinence before artificial urinary sphincter implantation. *Urology* 2009;73:1264–9.
- McGuire EJ, Woodside JR, Borden TA, et al. Prognostic value of urodynamic testing in myelodysplastic patients. *J Urol* 1981;126:205–9.
- Roth DR, Vyas PR, Kroovand RL, et al. Urinary tract deterioration associated with the artificial urinary sphincter. *J Urol* 1986;135:528–30.
- Scott FB, Fishman IJ, Shabsigh R. The impact of the artificial urinary sphincter in the neurogenic bladder on the upper urinary tracts. *J Urol* 1986;136: 636–42.
- Twiss C, Fleischmann N, Nitti VW. Correlation of abdominal leak point pressure with objective incontinence severity in men with post-radical prostatectomy stress incontinence. *Neurourol Urodyn* 2005;24: 207–10.
- James MH, McCammon KA. Artificial urinary sphincter for post-prostatectomy incontinence: A review. *Int J Urol* 2014;21:536–43.
- Peterson AC, Webster GD. Artificial urinary sphincter: Lessons learned. *Urol Clin North Am*. 2011;38:83–8, vii.
- Elliott DS, Barrett DM. Mayo Clinic long-term analysis of the functional durability of the AMS 800 artificial urinary sphincter: A review of 323 cases. *J Urol* 1998;159:1206–8.
- Lai HH, Hsu EI, Teh BS, et al. 13 years of experience with artificial urinary sphincter implantation at Baylor College of Medicine. *J Urol* 2007;177: 1021–5.
- Raj GV, Peterson AC, Toh KL, et al. Outcomes following revisions and secondary implantation of the artificial urinary sphincter. *J Urol* 2005; 173:1242–5.
- Van der Aa F, Drake MJ, Kasyan GR, et al. The artificial urinary sphincter after a quarter of a century: A critical systematic review of its use in male non-neurogenic incontinence. *Eur Urol* 2013;63:681–9.

28. Linder BJ, De Cogain M, Elliott DS. Long-term device outcomes of artificial urinary sphincter reimplantation following prior explantation for erosion or infection. *J Urol* 2014;191:734–8.
29. Gousse AE, Madjar S, Lambert MM, et al. Artificial urinary sphincter for post-radical prostatectomy urinary incontinence: Long-term subjective results. *J Urol* 2001;166:1755–8.
30. Elliott SP, Meng MV, Elkin EP, et al. Incidence of urethral stricture after primary treatment for prostate cancer: Data From CaPSURE. *J Urol* 2007;178:529–34; discussion 534.
31. Breyer BN, Davis CB, Cowan JE, et al. Incidence of bladder neck contracture after robot-assisted laparoscopic and open radical prostatectomy. *BJU Int* 2010;106:1734–8.
32. Herschorn S, Elliott S, Coburn M, et al. SIU/ICUD consultation on urethral strictures: Posterior urethral stenosis after treatment of prostate cancer. *Urology* 2014;83:559–70.
33. Gotto GT, Yunis LH, Vora K, et al. Impact of prior prostate radiation on complications after radical prostatectomy. *J Urol* 2010;184:136–42.
34. Pansadoro V, Emiliozzi P. Iatrogenic prostatic urethral strictures: Classification and endoscopic treatment. *Urology* 1999;53:784–9.
35. Surya BV, Provett J, Johanson KE, et al. Anastomotic strictures following radical prostatectomy: Risk factors and management. *J Urol* 1990;143:755–8.
36. Wessells H, Morey AF, McAninch JW. Obliterative vesicourethral strictures following radical prostatectomy for prostate cancer: Reconstructive armamentarium. *J Urol* 1998;160:1373–5.
37. Elliott DS, Boone TB. Combined stent and artificial urinary sphincter for management of severe recurrent bladder neck contracture and stress incontinence after prostatectomy: A long-term evaluation. *J Urol* 2001;165:413–5.
38. Yurkanin JP, Dalkin BL, Cui H. Evaluation of cold knife urethrotomy for the treatment of anastomotic stricture after radical retropubic prostatectomy. *J Urol* 2001;165:1545–8.
39. Anger JT, Raj GV, Delvecchio FC, et al. Anastomotic contracture and incontinence after radical prostatectomy: A graded approach to management. *J Urol* 2005;173:1143–6.
40. Simonato A, Gregori A, Lissiani A, et al. Two-stage transperineal management of posterior urethral strictures or bladder neck contractures associated with urinary incontinence after prostate surgery and endoscopic treatment failures. *Eur Urol* 2007;52:1499–504.
41. Elliott SP, McAninch JW, Chi T, et al. Management of severe urethral complications of prostate cancer therapy. *J Urol* 2006;176:2508–13.
42. Pfalzgraf D, Beuke M, Isbarn H, et al. Open retropubic reanastomosis for highly recurrent and complex bladder neck stenosis. *J Urol* 2011;186:1944–7.
43. Ramirez D, Zhao LC, Bagrodia A, et al. Deep lateral transurethral incisions for recurrent bladder neck contracture: Promising 5-year experience using a standardized approach. *Urology* 2013;82:1430–5.
44. Brede C, Angermeier K, Wood H. Continence outcomes after treatment of recalcitrant postprostatectomy bladder neck contracture and review of the literature. *Urology* 2014;83:648–52.
45. Mark S, Pérez LM, Webster GD. Synchronous management of anastomotic contracture and stress urinary incontinence following radical prostatectomy. *J Urol* 1994;151:1202–4.
46. Carr LK, Webster GD. Endoscopic management of the obliterated anastomosis following radical prostatectomy. *J Urol* 1996;156:70–2.
47. Borboroglu PG, Sands JP, Roberts JL, et al. Risk factors for vesicourethral anastomotic stricture after radical prostatectomy. *Urology* 2000;56:96–100.
48. Debell M, Wessells H. Recurrent bulbar urethral stricture in the region of an artificial urinary sphincter. *J Urol* 2001;166:1006–7.
49. Westney OL, Del Terzo MA, McGuire EJ. Balloon dilation of posterior urethral stricture secondary to radiation and cryotherapy in a patient with a functional artificial urethral sphincter. *J Endourol* 1999;13:585–6.
50. Wolf JS, Bennett CJ, Dmochowski RR, et al. Best practice policy statement on urologic surgery antimicrobial prophylaxis. *J Urol* 2008;179:1379–90.
51. Magera JS, Inman BA, Elliott DS. Does preoperative topical antimicrobial scrub reduce positive surgical site culture rates in men undergoing artificial urinary sphincter placement? *J Urol* 2007;178:1328–32; discussion 1332.
52. Walsh IK, Williams SG, Mahendra V, et al. Artificial urinary sphincter implantation in the irradiated patient: Safety, efficacy and satisfaction. *BJU Int* 2002;89:364–8.
53. Simhan J, Morey AF, Singla N, et al. 3.5 cm artificial urinary sphincter cuff erosion occurs predominantly in irradiated patients. *J Urol* 2015;193:593–7.
54. Manunta A, Guillé F, Patard JJ, et al. Artificial sphincter insertion after radiotherapy: Is it worthwhile? *BJU Int* 2000;85:490–2.
55. Hird AE, Radomski SB. Artificial urinary sphincter erosion after radical prostatectomy in patients treated with and without radiation. *Can Urol Assoc J* 2015;9:E554–558.
56. Bates AS, Martin RM, Terry TR. Complications following artificial urinary sphincter placement after radical prostatectomy and radiotherapy: A meta-analysis. *BJU Int* 2015;116:623–33.
57. Hudak SJ, Morey AF. Impact of 3.5cm artificial urinary sphincter cuff on primary and revision surgery for male stress urinary incontinence. *J Urol* 2011;186:1962–6.
58. Mahfouz W, Corcos J. What is the evidence supporting the implantation of an artificial urinary sphincter (AUS) before or after adjuvant radiotherapy in patients with post-prostatectomy incontinence? *Neurourol Urodyn* 2011;30:1405.
59. Lai HH, Boone TB. Implantation of artificial urinary sphincter in patients with post-prostatectomy incontinence, and preoperative overactive bladder and mixed symptoms. *J Urol* 2011;185:2254–9.
60. Warner MA, Warner DO, Harper CM, et al. Lower extremity neuropathies associated with lithotomy positions. *Anesthesiology* 2000;93:938–42.
61. Wilson SK, Aliotta PJ, Salem EA, et al. New enhancements of the scrotal one-incision technique for placement of artificial urinary sphincter allow proximal cuff placement. *J Sex Med* 2010;7:3510–5.
62. Tanner J, Norrie P, Melen K. Preoperative hair removal to reduce surgical site infection. *Cochrane Database Syst Rev* 2011;CD004122.
63. Grober ED, Domes T, Fanipour M, et al. Preoperative hair removal on the male genitalia: Clippers vs. razors. *J Sex Med* 2013;10:589–94.
64. Yeung LL, Grewal S, Bullock A, et al. A comparison of chlorhexidine-alcohol versus povidone-iodine for eliminating skin flora before genitourinary prosthetic surgery: A randomized controlled trial. *J Urol* 2013;189:136–40.
65. Henry GD, Kansal NS, Callaway M, et al. Centers of excellence concept and proline prostheses: An outcome analysis. *J Urol* 2009;181:1264–8.
66. Darouiche RO, Wall MJ, Itani KMF, et al. Chlorhexidine-Alcohol versus Povidone-iodine for Surgical-Site Antisepsis. *N Engl J Med* 2010;362:18–26.
67. Henry GD, Graham SM, Cleves MA, et al. Perineal approach for artificial urinary sphincter implantation appears to control male stress incontinence better than the transscrotal approach. *J Urol* 2008;179:1475–9; discussion 1479.
68. Kendirci M, Gupta S, Shaw K, et al. Synchronous prosthetic implantation through a transscrotal incision: An outcome analysis. *J Urol* 2006;175:2218–22.
69. Sotelo TM, Westney OL. Outcomes related to placing an artificial urinary sphincter using a single-incision, transverse-scrotal technique in high-risk patients. *BJU Int* 2008;101:1124–7.
70. Smith PJ, Hudak SJ, Scott JF, et al. Transcorporal artificial urinary sphincter cuff placement is associated with a higher risk of postoperative urinary retention. *Can J Urol* 2013;20:6773–7.
71. Rothschild J, Chang Kit L, Seltz L, et al. Difference between urethral circumference and artificial urinary sphincter cuff size, and its effect on postoperative incontinence. *J Urol* 2014;191:138–42.
72. Simhan J, Morey AF, Zhao LC, et al. Decreasing need for artificial urinary sphincter revision surgery by precise cuff sizing in men with spongiosal atrophy. *J Urol* 2014;192:798–803.
73. De Cógáin MR, Elliott DS. The impact of an antibiotic coating on the artificial urinary sphincter infection rate. *J Urol* 2013;190:113–7.
74. Scott FB. The artificial urinary sphincter. Experience in adults. *Urol Clin North Am* 1989;16:105–17.
75. Wilson SK, Delk JR. Ectopic placement of AMS 800 urinary control system pressure-regulating balloon. *Urology* 2005;65:167–70.
76. Chung PH, Morey AF, Tausch TJ, et al. High submuscular placement of urologic prosthetic balloons and reservoirs: 2-year experience and patient-reported outcomes. *Urology* 2014;84:1535–40.
77. Singla N, Siegel JA, Simhan J, et al. Does pressure regulating balloon location make a difference in functional outcomes of artificial urinary sphincter? *J Urol* 2015;194:202–6.
78. Petrou SP, Thiel DD, Elliot DS, et al. Does indigo carmine prevent early artificial urinary sphincter cuff erosion? *Can J Urol* 2006;13:3195–8.
79. Choe JM, Battino BS, Bell TE. Retrograde perfusion sphincterometry with a flexible cystoscope: Method of troubleshooting the AMS 800. *Urology* 2000;56:317–9.
80. Seideman CA, Zhao LC, Hudak SJ, et al. Is prolonged catheterization a risk factor for artificial urinary sphincter cuff erosion? *Urology* 2013;82:943–6.
81. Nauta M, Landsmeer MLA, Koren G. Codeine-acetaminophen versus nonsteroidal anti-inflammatory drugs in the treatment of post-abdominal surgery pain: A systematic review of randomized trials. *Am J Surg* 2009;198:256–61.
82. O'Connor RC, Gerber GS, Avila D, et al. Comparison of outcomes after single or DOUBLE-CUFF artificial urinary sphincter insertion. *Urology* 2003;62:723–6.
83. Sathianathan NJ, McGuigan SM, Moon DA. Outcomes of artificial urinary sphincter implantation in the irradiated patient. *BJU Int* 2014;113:636–41.
84. Bratzler DW, Dellinger EP, Olsen KM, et al. Clinical practice guidelines for antimicrobial prophylaxis in surgery. *Am J Health Syst Pharm* 2013;70:195–283.
85. Magera JS, Elliott DS. Artificial urinary sphincter infection: Causative organisms in a contemporary series. *J Urol* 2008;180:2475–8.
86. Léon P, Chartier-Kastler E, Roupert M, et al. Long-term functional outcomes after artificial urinary sphincter implantation in men with stress urinary incontinence. *BJU Int* 2015;115:951–7.
87. Linder BJ, Piotrowski JT, Ziegelmann MJ, et al. Perioperative complications following artificial urinary sphincter placement. *J Urol* 2015;194:716–20.

88. Ravier E, Fassi-Fehri H, Crouzet S, et al. Complications after artificial urinary sphincter implantation in patients with or without prior radiotherapy. *BJU Int* 2015;115:300–7.
89. Martins FE, Boyd SD. Post-operative risk factors associated with artificial urinary sphincter infection-erosion. *Br J Urol* 1995;75:354–8.
90. Klijn AJ, Hop WC, Mickisch G, et al. The artificial urinary sphincter in men incontinent after radical prostatectomy: 5 year actuarial adequate function rates. *Br J Urol* 1998;82:530–3.
91. Boscolo-Berto R, Raduazzo DI, Cecchetto G, et al. Urethral catheterization in men with artificial urinary sphincter: clinical and legal implications. *Urol J* 2012;9:611–3.
92. Di Benedetto P. Clean intermittent self-catheterization in neuro-urology. *Eur J Phys Rehabil Med* 2011;47:651–9.
93. Yates DR, Phé V, Roupêt M, et al. Robot-assisted laparoscopic artificial urinary sphincter insertion in men with neurogenic stress urinary incontinence. *BJU Int* 2013;111:1175–9.
94. Montague DK, Angermeier KW. Artificial urinary sphincter troubleshooting. *Urology* 2001;58:779–82.
95. Chung E, Cartmill R. Diagnostic challenges in the evaluation of persistent or recurrent urinary incontinence after artificial urinary sphincter (AUS) implantation in patients after prostatectomy. *BJU Int* 2013;112:32–5.
96. Saffarian A, Walsh K, Walsh IK, et al. Urethral atrophy after artificial urinary sphincter placement: is cuff downsizing effective? *J Urol* 2003;169:567–9.
97. Brito CG, Mulcahy JJ, Mitchell ME, et al. Use of a double cuff AMS800 urinary sphincter for severe stress incontinence. *J Urol* 1993;149:283–5.
98. Kabalin JN. Addition of a second urethral cuff to enhance performance of the artificial urinary sphincter. *J Urol* 1996;156:1302–4.
99. DiMarco DS, Elliott DS. Tandem cuff artificial urinary sphincter as a salvage procedure following failed primary sphincter placement for the treatment of post-prostatectomy incontinence. *J Urol* 2003;170:1252–4.
100. O'Connor RC, Lyon MB, Guralnick ML, et al. Long-term follow-up of single versus double cuff artificial urinary sphincter insertion for the treatment of severe postprostatectomy stress urinary incontinence. *Urology* 2008;71:90–3.
101. Guralnick ML, Miller E, Toh KL, et al. Transcortical artificial urinary sphincter cuff placement in cases requiring revision for erosion and urethral atrophy. *J Urol* 2002;167:2075–8; discussion 2079.
102. Wiedemann L, Cornu J-N, Haab E, et al. Transcortical artificial urinary sphincter implantation as a salvage surgical procedure for challenging cases of male stress urinary incontinence: Surgical technique and functional outcomes in a contemporary series. *BJU Int* 2013;112:1163–8.
103. Mock S, Dmochowski RR, Brown ET, et al. The impact of urethral risk factors on transcortical artificial urinary sphincter erosion rates and device survival. *J Urol* 2015;194:1692–6.
104. Hajivassiliou CA. A review of the complications and results of implantation of the AMS artificial urinary sphincter. *Eur Urol* 1999;35:36–44.
105. Kowalczyk JJ, Nelson R, Mulcahy JJ. Successful reinsertion of the artificial urinary sphincter after removal for erosion or infection. *Urology* 1996;48:906–8.
106. Motley RC, Barrett DM. Artificial urinary sphincter cuff erosion. Experience with reimplantation in 38 patients. *Urology* 1990;35:215–8.
107. Brant WO, Erickson BA, Elliott SP, et al. Risk factors for erosion of artificial urinary sphincters: A multicenter prospective study. *Urology* 2014;84:934–8.
108. Singla N, Singla AK. Review of single-surgeon 10-year experience with artificial urinary sphincter with report of sterile cuff erosion managed nonsurgically. *Urology* 2015;85:252–6.
109. Trost L, Elliott D. Small intestinal submucosa urethral wrap at the time of artificial urinary sphincter placement as a salvage treatment option for patients with persistent/recurrent incontinence following multiple prior sphincter failures and erosions. *Urology* 2012;79:933–8.
110. Rehder P, Pinggera G-M, Mitterberger M, et al. Urethral support with PelviSoft after artificial urinary sphincter erosion at revision procedures. *Wien Med Wochenschr* 2007;157:170–2.
111. Rozanski AT, Tausch TJ, Ramirez D, et al. Immediate urethral repair during explantation prevents stricture formation after artificial urinary sphincter cuff erosion. *J Urol* 2014;192:442–6.
112. Magera JS, Elliott DS. Tandem transcortical artificial urinary sphincter cuff salvage technique: Surgical description and results. *J Urol* 2007;177:1015–9; discussion 1019–1020.
113. Maillat F, Buzelin J-M, Bouchot O, et al. Management of artificial urinary sphincter dysfunction. *Eur. Urol.* 2004;46:241–5. discussion 246.
114. Selph JP, Belsante MJ, Gupta S, et al. The ohmmeter identifies the site of fluid leakage during artificial urinary sphincter revision surgery. *J Urol* 2015;194:1043–8.
115. Linder BJ, Rivera ME, Ziegelmann MJ, et al. Long-term outcomes following artificial urinary sphincter placement: An analysis of 1082 cases at mayo clinic. *Urology* 2015;86:602–7.
116. Nitti VW, Mourtzinos A, Brucker BM, SUFU Pad Test Study Group. Correlation of patient perception of pad use with objective degree of incontinence measured by pad test in men with post-prostatectomy incontinence: The SUFU Pad Test Study. *J Urol* 2014;192:836–42.
117. Parulkar BG, Barrett DM. Combined implantation of artificial sphincter and penile prosthesis. *J Urol* 1989;142:732–5.
118. Zafirakis H, Wang R, Westney OL. Combination therapy for male erectile dysfunction and urinary incontinence. *Asian J Androl* 2008;10:149–54.
119. Mancini JG, Kizer WS, Jones LA, et al. Patient satisfaction after dual implantation of inflatable penile and artificial urinary sphincter prostheses. *Urology* 2008;71:893–6.
120. Segal RL, Cabrini MR, Harris ED, et al. Combined inflatable penile prosthesis-artificial urinary sphincter implantation: No increased risk of adverse events compared to single or staged device implantation. *J Urol* 2013;190:2183–8.
121. Chartier Kastler E, Genevois S, Gamé X, et al. Treatment of neurogenic male urinary incontinence related to intrinsic sphincter insufficiency with an artificial urinary sphincter: A French retrospective multicentre study. *BJU Int* 2011;107:426–32.
122. Costa P, Poinas G, Ben Naoum K, et al. Long-term results of artificial urinary sphincter for women with type III stress urinary incontinence. *Eur Urol* 2013;63:753–8.
123. Kryger JV, Levenson G, González R. Long-term results of artificial urinary sphincters in children are independent of age at implantation. *J. Urol.* 2001;165:2377–9.
124. Aliabadi H, Gonzalez R. Success of the artificial urinary sphincter after failed surgery for incontinence. *J Urol* 1990;143:987–90.
125. Spiess PE, Capolicchio JP, Kiruluta G, et al. Is an artificial sphincter the best choice for incontinent boys with Spina Bifida? Review of our long term experience with the AS-800 artificial sphincter. *Can J Urol* 2002;9:1486–91.
126. Castera R, Podestà ML, Ruarte A, et al. 10-Year experience with artificial urinary sphincter in children and adolescents. *J Urol* 2001;165:2373–6.
127. Simeoni J, Guys JM, Mollard P, et al. Artificial urinary sphincter implantation for neurogenic bladder: A multi-institutional study in 107 children. *Br J Urol* 1996;78:287–93.
128. Holmes NM, Kogan BA, Baskin LS. Placement of artificial urinary sphincter in children and simultaneous gastrocystoplasty. *J Urol* 2001;165:2366–8.
129. Singh G, Thomas DG. Artificial urinary sphincter in patients with neurogenic bladder dysfunction. *Br J Urol* 1996;77:252–5.
130. Bersch U, Göcking K, Pannek J. The artificial urinary sphincter in patients with spinal cord lesion: Description of a modified technique and clinical results. *Eur Urol* 2009;55:687–93.
131. Light JK, Lapin S, Vohra S. Combined use of bowel and the artificial urinary sphincter in reconstruction of the lower urinary tract: Infectious complications. *J Urol* 1995;153:331–3.
132. Ter Meulen PH, Berghmans LCM, Van Kerrebroeck PEVA. Systematic review: Efficacy of silicone microimplants (Macroplastique) therapy for stress urinary incontinence in adult women. *Eur Urol* 2003;44:573–82.
133. Mehnert U, Bastien L, Denys P, et al. Treatment of neurogenic stress urinary incontinence using an adjustable continence device: 4-year followup. *J Urol* 2012;188:2274–80.
134. Gonzalez R, Merino FG, Vaughn M. Long-term results of the artificial urinary sphincter in male patients with neurogenic bladder. *J Urol* 1995;154:769–70.
135. Sedor J, Mulholland SG. Hospital-acquired urinary tract infections associated with the indwelling catheter. *Urol Clin North Am* 1999;26:821–8.
136. Richard F, Committee on Women's Urology and Pelviperineology, French Association of Urology. Guidelines for the treatment of non-neurological urinary incontinence in women using the artificial urinary sphincter. *Prog Urol* 2010;20:S155–160.
137. Lucas MG, Bosch RJJ, Burkhard FC, et al. EAU guidelines on surgical treatment of urinary incontinence. *Eur Urol* 2012;62:1118–29.
138. Light JK, Scott FB. Management of urinary incontinence in women with the artificial urinary sphincter. *J Urol* 1985;134:476–8.
139. Diokno AC, Hollander JB, Alderson TP. Artificial urinary sphincter for recurrent female urinary incontinence: Indications and results. *J Urol* 1987;138:778–80.
140. Webster GD, Perez LM, Khoury JM, et al. Management of type III stress urinary incontinence using artificial urinary sphincter. *Urology* 1992;39:499–503.
141. Thomas K, Venn SN, Mundy AR. Outcome of the artificial urinary sphincter in female patients. *J Urol* 2002;167:1720–2.
142. Chung E, Cartmill RA. 25-year experience in the outcome of artificial urinary sphincter in the treatment of female urinary incontinence. *BJU Int* 2010;106:1664–7.
143. Vayleux B, Rigaud J, Luyckx F, et al. Female urinary incontinence and artificial urinary sphincter: Study of efficacy and risk factors for failure and complications. *Eur Urol* 2011;59:1048–53.
144. Revaux A, Roupêt M, Seringe E, et al. Is the implantation of an artificial urinary sphincter with a large cuff in women with severe urinary incontinence associated with worse perioperative complications and functional outcomes than usual? *Int Urogynecol J* 2011;22:1319–24.
145. Chartier-Kastler E, Van Kerrebroeck P, Olinas R, et al. Artificial urinary sphincter (AMS 800) implantation for women with intrinsic sphincter deficiency: A technique for insiders? *BJU Int* 2011;107:1618–26.
146. Zimmern PE, Gormley EA, Stoddard AM, et al. Management of recurrent stress urinary incontinence after burch and sling procedures. *Neurourol Urodyn* 2016;35:344–8.
147. Brubaker L, Litman HJ, Kim H-Y, et al. Missing data frequency and correlates in two randomized surgical trials for urinary incontinence in women. *Int Urogynecol J* 2015;26:1155–9.

148. Roupřet M, Misraï V, Vaessen C, et al. Laparoscopic approach for artificial urinary sphincter implantation in women with intrinsic sphincter deficiency incontinence: A single-centre preliminary experience. *Eur Urol* 2010;57:499–504.
149. Mandron E, Bryckaert P-E, Papatsoris AG. Laparoscopic artificial urinary sphincter implantation for female genuine stress urinary incontinence: Technique and 4-year experience in 25 patients. *BJU Int* 2010;106:1194–8; discussion 1198.
150. Ngninkeu BN, Van Heugen G, Di Gregorio M, et al. Laparoscopic artificial urinary sphincter in women for type III incontinence: Preliminary results. *Eur Urol* 2005;47:793–7; discussion 797.
151. Fournier G, Callerot P, Thoulouzan M, et al. Robotic-assisted laparoscopic implantation of artificial urinary sphincter in women with intrinsic sphincter deficiency incontinence: Initial results. *Urology* 2014;84:1094–8.
152. Biardeau X, Rizk J, Marcelli F, et al. Robot-assisted laparoscopic approach for artificial urinary sphincter implantation in 11 women with urinary stress incontinence: Surgical technique and initial experience. *Eur Urol* 2015;67:937–42.
153. Knight SL, Susser J, Greenwell T, et al. A new artificial urinary sphincter with conditional occlusion for stress urinary incontinence: Preliminary clinical results. *Eur Urol* 2006;50:574–80.
154. Müller B, Deyhle H, Mushkolaj S, et al. The challenges in artificial muscle research to treat incontinence. *Swiss Med Wkly* 2009;139:591–5.
155. Lamraoui H, Bonvilain A, Robain G, et al. Development of a novel artificial urinary sphincter: A versatile automated device. *IEEE/ASME Trans Mechatron* 2010;15:916–24.
156. Ruthmann O, Richter S, Seifert G, et al. The first teleautomatic low-voltage prosthesis with multiple therapeutic applications: A new version of the german artificial sphincter system. *Artif Organs* 2010;34:635–41.
157. Schiavini JL, Damião R, De Resende JAD, Jr., et al. Treatment of post-prostate surgery urinary incontinence with the periurethral constrictor: A retrospective analysis. *Urology* 2010;75:1488–92.
158. Malaeb BS, Elliott SP, Lee J, et al. Novel artificial urinary sphincter in the canine model: The tape mechanical occlusive device. *Urology* 2011;77:211–6.
159. Staerman F, G-Llorens C, Leon P, et al. ZSI 375 artificial urinary sphincter for male urinary incontinence: A preliminary study. *BJU Int* 2013;111:E202–6.
160. Valerio M, Jichlinski P, Dahlem R, et al. Experimental evaluation of an electromechanical artificial urinary sphincter in an animal model. *BJU Int* 2013;112:E337–343.
161. Hached S, Saadaoui Z, Loutochin O, et al. Novel, wirelessly controlled, and adaptive artificial urinary sphincter. *IEEE/ASME Trans Mechatron* 2015; PP:1–3.
162. Chung E, Ranaweera M, Cartmill R. Newer and novel artificial urinary sphincters (AUS): The development of alternatives to the current AUS device. *BJU Int* 2012;110:5–11.
163. Phé V, Roupřet M, Chartier-Kastler E. Newer and novel artificial urinary sphincters (AUS): The development of alternatives to the current AUS device. *BJU Int* 2013;112:E426–428.
164. Bettez M, Tu LM, Carlson K, et al. 2012 Update: Guidelines for adult urinary incontinence collaborative consensus document for the canadian urological association. *Can Urol Assoc J* 2012;6:354–63.
165. Hached S, Trigui A, El Khalloufi I, et al. A Bluetooth-based Low-Energy Qi-compliant battery charger for implantable medical devices. 2014 IEEE International Symposium on Bioelectronics and Bioinformatics (ISBB). 2014. page 1–4.
166. Elliott DS, Barrett DM, Gohma M, et al. Does nocturnal deactivation of the artificial urinary sphincter lessen the risk of urethral atrophy? *Urology* 2001;57:1051–4.
167. García Montes F, Mundy AR, Knight SI, et al. The role of low urethral mucosal and submucosal blood perfusion in patients with artificial urinary sphincters. *Actas Urol Esp* 2007;31:482–7.
168. Eswara JR, Chan R, Vetter JM, et al. Revision techniques after artificial urinary sphincter failure in men: Results from a multicenter study. *Urology* 2015;86:176–80.
169. Hussain M, Greenwell TJ, Venn SN, et al. The current role of the artificial urinary sphincter for the treatment of urinary incontinence. *J Urol* 2005;174:418–24.
170. Islah M, Cho SY, Son H. The current role of the artificial urinary sphincter in male and female urinary incontinence. *World J Mens Health* 2013;31:21–30.
171. Elliott DS, Timm GW, Barrett DM. An implantable mechanical urinary sphincter: A new nonhydraulic design concept. *Urology* 1998;52:1151–4.
172. Vakalopoulos I, Kampantais S, Laskaridis L, et al. New artificial urinary sphincter devices in the treatment of male iatrogenic incontinence. *Adv Urol* 2012;2012:e439372.
173. Trolliet S, Mandron E, Lang H, et al. Laparoscopic approach for artificial urinary sphincter implantation for women with severe stress urinary incontinence. *Prog Urol* 2013;23:877–83.