

**W12: Pelvic Floor Ultrasound**  
Workshop Chair: Hans Peter Dietz, Australia  
20 October 2014 14:00 - 18:00

Start	End	Topic	Speakers
14:00	14:15	Introduction	• Hans Peter Dietz
14:15	14:45	Anterior Compartment	• Ka Lai Shek
14:45	15:00	Live scan	• Zsuzsanna Jármy Di Bella
15:00	15:30	Posterior Compartment	• Rodrigo Guzman Rojas
15:30	16:00	Break	None
16:00	16:30	Slings and meshes	• Kamil Svabik
16:30	16:45	Live scan	• Zsuzsanna Jármy Di Bella
16:45	17:30	Levator assessment	• Hans Peter Dietz
17:30	17:45	Live Scan	• Zsuzsanna Jármy Di Bella
17:45	18:00	Discussion	All

**Aims of course/workshop**

This workshop will familiarize attendees with the basic methodology and clinical uses of pelvic floor ultrasound imaging, both using 2D ultrasound and 3D/4D technology, including the detection and assessment of pelvic floor trauma. The live scanning segment will provide for limited hands-on opportunity in normal volunteers and patients with urinary incontinence and female pelvic organ prolapse, before and after surgical intervention. We will provide a DVD with de-identified cases for offline analysis and a palpation model for the teaching of the diagnosis of levator trauma by palpation.

# 1 Introduction and Anterior Compartment

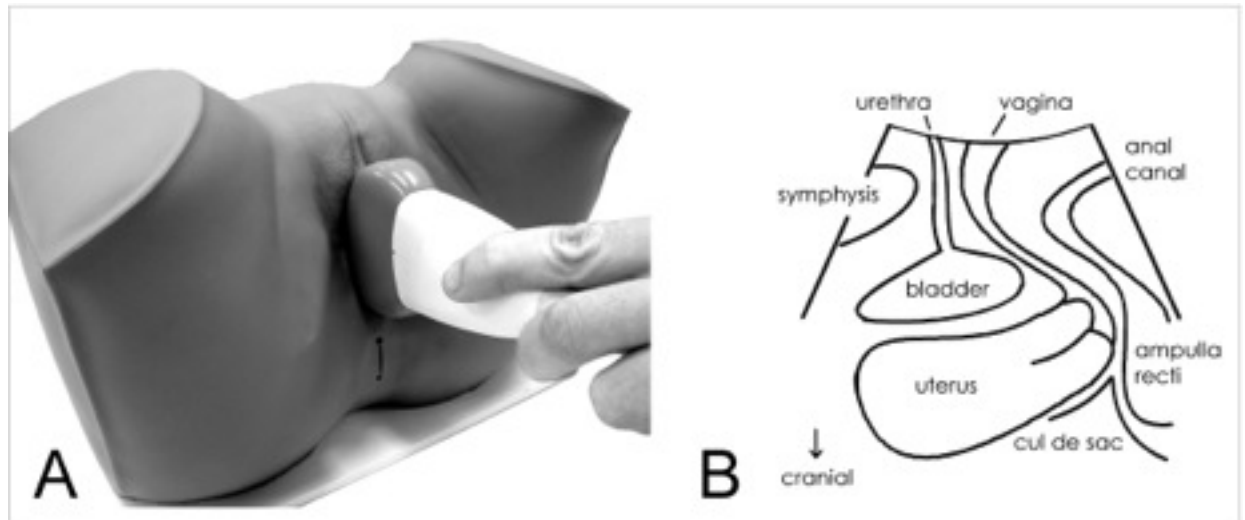


Fig. 1: Standard transducer placement for translabial ultrasound (A) and image orientation in the midsagittal plane (B).

Imaging plays a growing role in the investigation of pelvic floor disorders, especially translabial or perineal ultrasound. With this method most structures of interest in pelvic floor disorders can be observed in the near field, at high frequencies, and with sufficient clarity due to excellent tissue discrimination between urethra, bladder, vagina, anorectum and levator muscle.

The original indication for translabial or transperineal ultrasound was (and still is) the determination of **bladder neck mobility**. This is done against the reference of either the inferior margin of the symphysis, or against the central axis of the same. The former is more convenient, the latter may be marginally more repeatable. However, modern systems allow much more than determination of bladder neck mobility. Mobility of the entire urethra can be determined, which has shown that it is the **mid-urethra**, rather than the bladder neck, that matters most for stress continence, and that pregnancy, rather than childbirth, influences this parameter.

Translabial ultrasound is also helpful in determining **residual urine**, **detrusor wall thickness**, urethral integrity, the retrovesical angle, urethral rotation and cystocele descent. It distinguishes between two distinct forms of **cystocele** (Green Type 2 and 3), which have very different implications for function. Cystoceles with an open retrovesical angle and **funnelling** are the commonest anatomical correlate of stress urinary incontinence (Green 2), and cystoceles with intact retrovesical angle (Green 3) are usually found in women with symptoms of prolapse and voiding dysfunction. Even more interesting, one is associated with an intact pelvic floor muscle, the other with levator avulsion. Translabial ultrasound graphically shows **urethral kinking** in women with prolapse, potentially explaining voiding dysfunction. It is at least equivalent to other imaging methods in visualising **urethral diverticula**, Gartner duct cysts and **suburethral slings**. Ultrasound is the only method able to image modern mesh slings and implants, and may predict who actually needs such implants.

## 2 Posterior Compartment

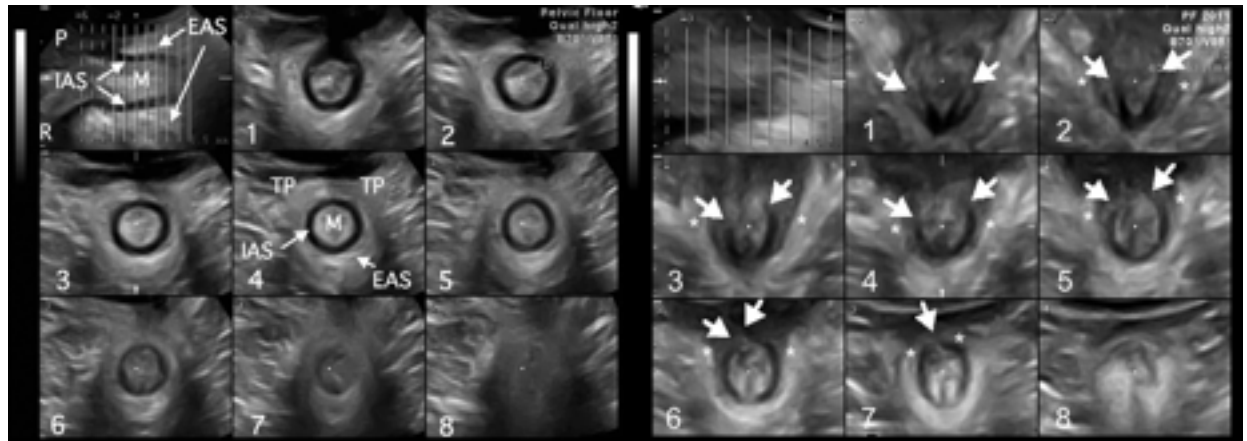


Fig. 2: Translabial tomographic anal sphincter imaging. Normal anatomy (left block of images) and major EAS/ IAS defects 2 months after OASIS repair.

Pelvic floor ultrasound is particularly useful in the posterior compartment, and we have in no way realised its potential benefits for clinical practice. We see descent of the posterior vaginal wall and diagnose a 'rectocele', usually quite unaware that at least five different anatomically distinct conditions can cause this appearance.

A Stage II rectocele observed on clinical examination could be due to a **true rectocele**, i.e., a defect of the rectovaginal septum (most common, and associated with symptoms of prolapse, incomplete bowel emptying and straining at stool), due to an abnormally distensible, intact rectovaginal septum (common and associated only with prolapse symptoms), a combined **recto- enterocele** (less common), an isolated **enterocele** (uncommon), or just a deficient perineum giving the impression of a 'bulge'. Occasionally a 'rectocele' turns out to be a **rectal intussusception**, an early stage of **rectal prolapse**, where the wall of the rectal ampulla is inverted and enters the anal canal on Valsalva. This condition is not uncommon in urogynecological patients and strongly associated with abnormal levator ani morphology and function.

This segment of the talk will demonstrate the main abnormalities observed on translabial/ transperineal ultrasound and discuss the significance of those findings for symptoms and surgical correction. At a time when there is such widespread confusion regarding the aetiology, nature, relevance and surgical treatment of even the most common clinical conditions, it is very unlikely that substantial progress can be made without a cheap, universally available form of imaging. Translabial ultrasound provides such a method. In addition, this form of imaging can provide information on the anal canal and sphincter at no additional cost or inconvenience, at a quality that exceeds that of transanal imaging (see Figure 2). As a result, it is now possible to provide comprehensive high- quality noninvasive imaging in the postnatal period at very low cost and with little inconvenience for the patient, which opens up multiple opportunities for obstetric practice improvement.

### 3 Slings and meshes

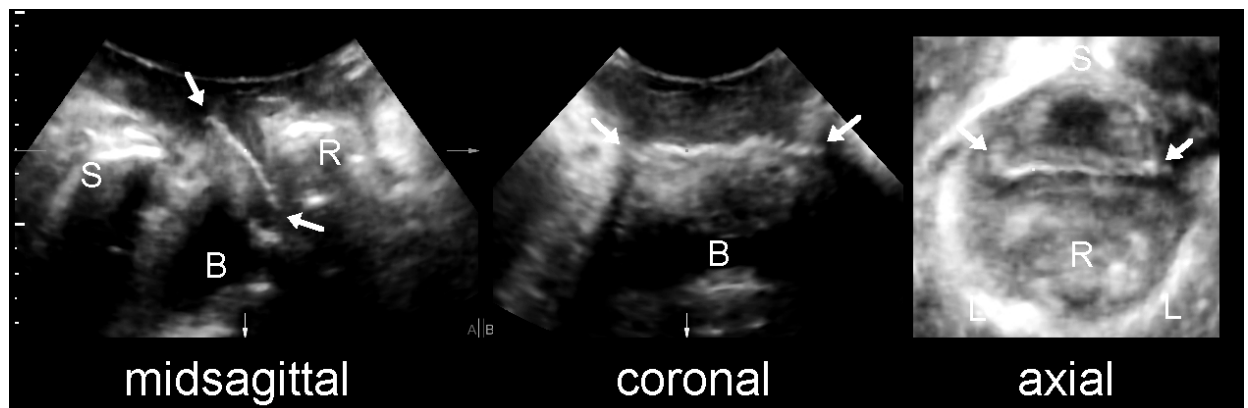


Fig. 3: A transobturator mesh, as seen in the midsagittal (left), coronal (middle) and axial plane (right).

Since the late 1990s synthetic **suburethral slings** have become very popular. Ultrasound can confirm the presence of such a sling, distinguish between transobturator and transretzius implants, especially when examining the axial plane, and allow an educated guess regarding the type of implant. As these meshes are highly echogenic, ultrasound is superior to MR in identifying implants and has helped elucidate their mode of action. It is also very helpful when assessing women with complications of suburethral slings such as voiding dysfunction and de novo symptoms of urgency, helping the surgeon to decide whether to cut a sling.

There is a worldwide trend towards the use of permanent **vaginal wall meshes**, especially for recurrent prolapse, and complications such as support failure, mesh erosion and chronic pain are not that uncommon. Polypropylene meshes are highly echogenic (see Figure 3), and their visibility is limited only by persistent prolapse and distance from the transducer.

3D translabial ultrasound has demonstrated that the implanted mesh often is nowhere near as wide as it is supposed to be. Surgical technique seems to play a role here as fixation of mesh to underlying tissues results in a flatter, more even appearance. The position, extent and mobility of vaginal wall mesh can be determined, helping with the assessment of individual technique, and ultrasound may uncover complications such as dislodgment of anchoring arms. Meshes are only as supportive as their anchoring allows them to be. Translabial 4D ultrasound is useful in determining functional outcome and location of implants, and has helped define different forms of recurrence. It is of importance in evaluating implant designs and surgical techniques. And finally, the identification of levator avulsion and hiatal ballooning provides objective criteria for the selection of patients at high risk of prolapse recurrence, allowing more rational use of prolapse mesh implants.

## 4 Pelvic Floor Trauma

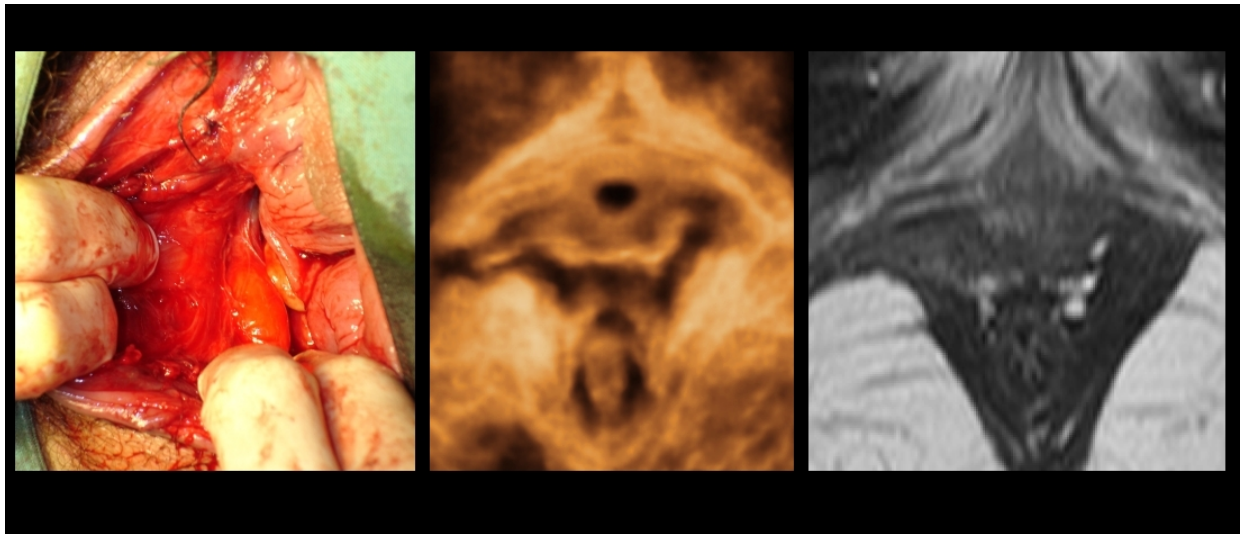


Fig. 4: Typical right-sided avulsion of the puborectalis muscle as seen in Delivery Suite (left), on translabial 4D US (middle) and on MR (right).

Major delivery- related trauma of the puborectalis muscle (**'avulsion'**, see Figure 4) is a major factor in the aetiology of female pelvic organ prolapse. It occurs in 10-30% of first vaginal deliveries, more commonly after Forceps and in older primiparae, and is strongly associated with **cystocele and uterine prolapse**, and with **recurrence** after prolapse surgery. Avulsion reduces pelvic floor muscle function by about one third and has a marked effect on hiatal biometry and distensibility. In the past it was generally assumed that abnormal muscle function was due to neuropathy, but damage to the innervation of the levator ani muscle is likely to play a much smaller role compared to direct trauma.

These defects are palpable, but palpation requires significant teaching and is clearly less repeatable than identification by ultrasound. Identification of an avulsion injury is aided by measurement of the **'levator- urethra gap'**, the distance from the center of the urethral lumen to the most medial aspect of the puborectalis muscle, and **tomographic US** is particularly useful.

Avulsion injury does not seem to be associated with stress urinary incontinence and urodynamic stress incontinence, nor does it seem to matter much for faecal incontinence. Despite this there seems to be a high prevalence of levator defects in women with anal sphincter defects, which is not really surprising given the overlap in risk factors. Bilateral defects are more difficult to detect since there is no normal side to compare with, but they have a particularly severe impact on pelvic floor function and organ support.

Avulsion is a major risk factor for prolapse recurrence after surgical reconstruction, and this is also true for irreversible overdilation of the levator hiatus which affects even more women than outright levator muscle tears. Both factors can help select patients for mesh use and may be used as entry criteria for trials testing new surgical techniques.